

CHERUBISM – A FIBRO-OSSEOUS DISORDER MIMICKING AMELOBLASTOMA: A CASE REPORT

ADIT SRIVASTAVA^{a1}, RAHUL AGRAWAL^b, H.C. BARANWAL^c AND SRISHTI SRIVASTAVA^d

^{abcd}Faculty of Dental Sciences, IMS, BHU, Varanasi, Uttar Pradesh, India

ABSTRACT

Cherubism is a rare fibro-osseous disorder characterized by plump cheeked (cherubic) appearance of the patient. There is a painless often bilateral enlargement of the jaws, in which bone is replaced with fibrous tissue. In most of the cases cherubism appearance regressed without treatment after puberty. On extraoral radiography, the lesions exhibit bilateral multilocular radiolucent areas especially in mandibular ramus area. The present case report describes cherubism in a 16yrs old female who presented with painless facial swelling almost mimicking ameloblastoma clinically as well as radiographically.

KEYWORDS: Cherubism, Fibro Osseous, Multilocular Radiolucency, Fibrous Dysplasia.

Cherubism is a non-neoplastic condition of the jaws which is also known as ‘familial fibrous dysplasia of the jaws or ‘familial multilocular cystic disease of the jaws’. It is an autosomal dominant disorder. It was first described by Jones in 1933 (Jones WA ,1933). Usually it is found in the children around 2 to 20 yrs of age and it is characterized by progressive painless bilateral swelling of jaws involving either maxilla or mandible or sometimes both producing pumped cheeked face (cherubic face appearance) (Ongole et al.,2010). Swelling in cherubism is firm and hard on palpation with intact overlying mucosa .Intraoral swelling of the alveolar ridge may occur in some cases.

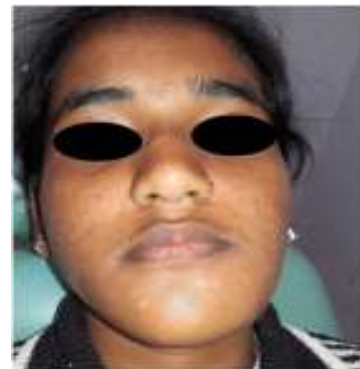Pulling or stretching of the skin of the cheek, depresses the lower eyelid, exposing a thin line of sclera will give a classic eye to heaven appearance in some patients. There is a rapid increase in size up to 7-8 yrs of age after that the lesion become static or progress very slow until puberty and regress after puberty.

We present a case of cherubism in which the lesion was still progressing after the age of 16 years and overall growth pattern mimicked Ameloblastoma.

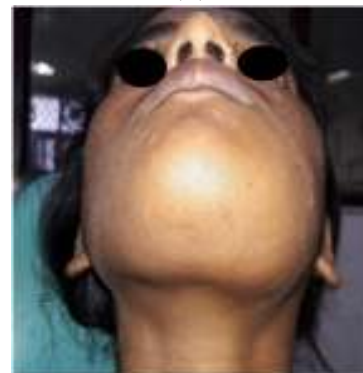CASE REPORT

A 16yrs old girl came to the department of oral medicine and radiology IMS, BHU Varanasi with the complain of swelling on the face since 4-5yrs. patient become aware of swelling around swelling 4-5yr back which was initially small in size painless and slowly increased to present side. On the examination there was extraoral bilateral swelling involving whole mandibular region (fig1-A). Swelling was more slightly prominent on left side of the face as compared with right side (fig 1-B). There was no pain associated with the swelling, and no local rise in temperature was noticed. Overlying skin was normal. No lymph node enlargement of submandibular, submental, cervical group of lymph node was noticed. No paraesthesia was seen. On the

intraoral examination nothing abnormal was detected (Fig 2-A&B). Pt. was subjected to radiographic examination. Panoramic radiograph (OPG) showed generalised multicystic radiolucency extending from left ramus of mandible to right body of the mandible (Fig-3). Both side mandibular 3rd molar tooth buds were missing. On the basis of the clinical features and radiographic features provisional diagnosis of ameloblastoma was made. Under the differential diagnosis the following lesions were considered cherubism, central giant cell granuloma, giant cell lesion of hyperpara thyroidism , central heamgioma.

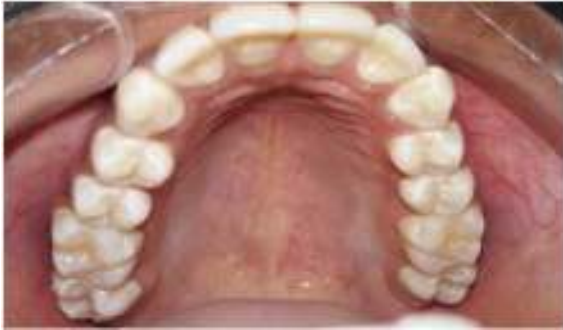

(A)

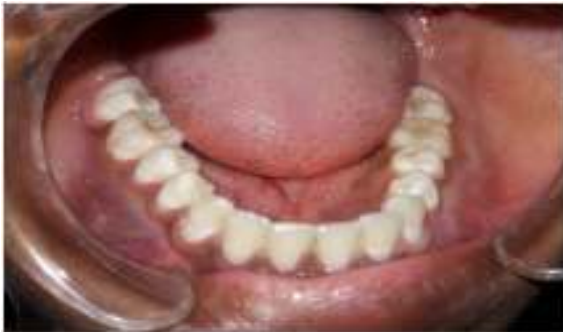

(B)

Figure 1A&B: Showing bilateral swelling more on the right side of the face.



(A)



(B)

Figure 2 A&B: Intraoral photograph of the patient

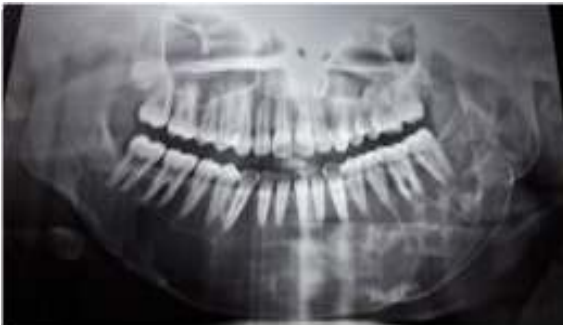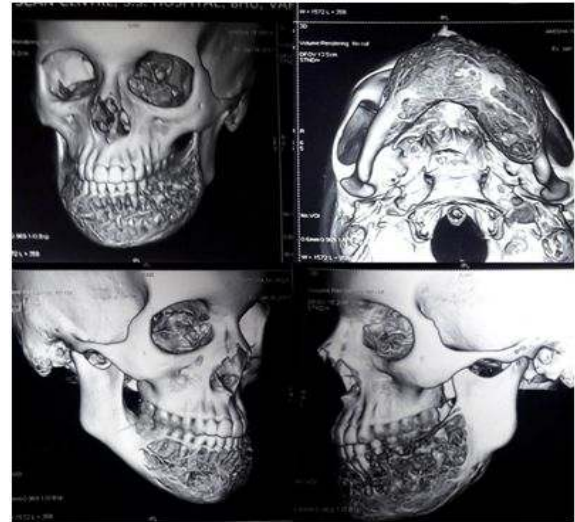


Figure 3: Panoramic radiograph (OPG) is showing the generalised multilocular radiolucency

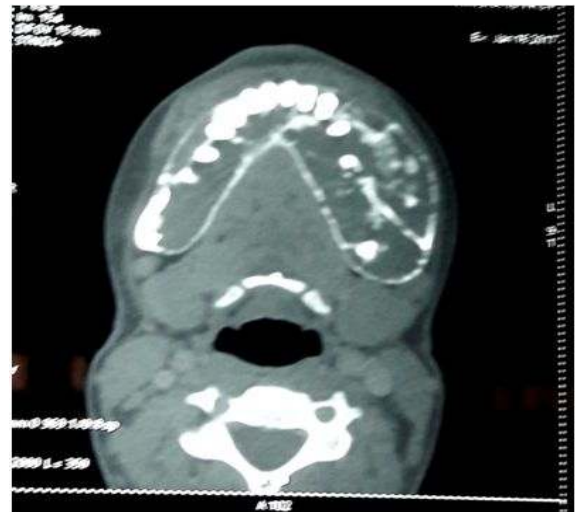Blood investigations, serum calcium, PTH level, serum phosphorus and alkaline phosphates levels were within the normal limits .

As the lesion was very large we decided to go for the CT scan of the face , CT scan showed bony expansion bilaterally mandibular anterior region involving symphysis menti and body of mandible reaching upto the left angle of mandible (Fig-4 A&B) .There was thinning of buccal as well as lingual cortex of the mandible seen. There was no evidence of soft tissue component in the CT scan. CT scan reports were more in favour of CHERUBISM. For the confirmation of the diagnosis we decided to go for incisional biopsy of the lesion. Histological examination revealed a fibroblast like cells with a large number of

multinucleated giant cells and perivascular eosinophilic cuffing was seen. Which were consistent with the diagnosis of cherubism.



(A)



(B)

Figure 4 A&B: CT scan showing bony expansion bilaterally anterior mandibular region involving symphysis menti and body of mandible reaching upto the left angle of mandible

All pro's and con's were explained to the patient and it decided to keep the patient under follow up till age of puberty after which surgical shaving to correct the bony deformities if present was planned.

Usually the bony architecture returns to normal by age of 30, except in few cases in which involved bone of ramus retains a ground glass appearance.

DISCUSSION

According to the World Health Organization classification, Cherubism is a benign hereditary

condition of the jaws, usually found in children by 5 years of age. It is a familial disease and presents an autosomal dominant tendency with 100% in males and 50–70% in females (Lima et al., 2010) (Kaur et al., 2014). Males are more affected than Female at the proportion of 2:1 (Kaugars et al., 1992).

Depends on the severity, location of the lesion and the extent to which jaws are affected it is divided into three grade (Arnott-1978) [Grade – I ,II &III] Grade I - It is primarily in the ramus of the mandible Grade II -In more severe cases , the ramus and the body the mandible are involved resulting in congenital absence of the 3rd mandibular molar and occasionally the 2nd mandibular molar. Tuberosity region of maxilla is also affected Grade III -In these cases , the lesion affects the maxilla and mandible entirely except the coronoid process and condyles and may result in considerable facial deformities. Mutation in the SH3BP2 (SH3 domain binding protein2) gene have been identified in about 80% of people with cherubism. Mutation in the SH3BP2 gene lead to the production of an overactive version of protein which disrupt critical signaling pathways in cells associated with maintenance of the bone tissue (Sultana et al., 2012),(Papadaki et al., 2012). A combination of bone loss and inflammation leads to formation of the cyst like growth which is characteristic of cherubism (Lannon and Earley 2010). Cherubism can be non-aggressive and aggressive on the basis of clinical behavior and radiographic findings. Non-aggressive lesions are most frequently present in young adults, the aggressive form of cherubism occur in young children which is rapidly growing and may cause thinning and perforation of cortical bone tooth displacement and root resorption (Lannon and Earley 2010). Our case resembled Ameloblastoma due to rapid growth pattern. But no root resorption was seen , which is one of the classic feature of ameloblastoma and ameloblastoma generally occurs above 40yrs of age.

Cherubism lesions resemble giant cell tumors because histologically they contain many giant-cells and mononuclear or stromal cells (Octavian et al., 2014). Radiologically cherubism is multilocular whereas in central giant cell granuloma the lesions are unilocular(Silva et al., 2007).

In most of the cases cherubism regressed without any treatment after puberty. If any asymmetry is seen after the regression can be corrected by decortications of the bone and osseous shaving.

In our case both third molar tooth buds were not seen on radiographs and lesion involved both sides

ramus and body of which showed it was grade II type of cherubism. Our case was unique because the patient noticed the swelling late in the patient life after 10yrs of age and radiographically it resembled more like ameloblastoma due to its massive growth.

CONCLUSION

Cherubism is a rare fibro-osseous disorder, which is self-limiting. Surgery to correct the jaw deformities is indicated if aesthetic and functional concern is required.

REFERENCES

- Jones W.A., 1933. Familial multilocular cystic disease of the jaws. *Am. J. Cancer*, **17**:946–501.
- Ongole R. and Praveen B.N., 2010. Section VII chapter **22**, Textbook of oral medicine, oral diagnosis and oral radiology 642-643.
- Gabriela de M.G.L., Almeida J.D. and Cabral L.A.G., 2010. Cherubism: Clinicoradiographic Features and Treatment. *Journal of oral and maxillofacial research*, **1**:2-8.
- Kaur M., Shah S., Babaji P., Singh J., Nair D. and Kamble S.S., 2014. Cherubism: A rare case report. *J Nat Sci Biol Med.*, **5**(2):488–491.
- Kaugars G. E., Niamtu J. and Svirsky J. A., 1992. Cherubism: diagnosis, treatment, and comparison with central giant cell granulomas and giant cell tumors., *Oral Surgery Oral Medicine and Oral Pathology*, **73**(3):369–374.
- Sultana N. and Sham M. E., 2012. Cherubism- A Case Report. *Int. J. Dent. Clinics.*, **4**(2): 60-62.
- Papadaki M.E., Lietman S.A., Levine M.A., Olsen B.R., Kaban L.B. and Reichenberger E.J., 2012. Cherubism: best clinical practice. *Orphanet J Rare Dis.*, **7**(1) S6, 1750-1172-7-S1-S6.
- Lannon D.A. and Earley M.J., 2001. Cherubism and its charlatans. *British Journal Plastic Surgery*, **54**(8):708-11.
- Octavian D., Emilia S., Cristian V., Dana C.B. and Alexandru B., 2014. Cherubism: a case report. *Rom J Morphol Embryol*, **55**(2):655–658.
- Silva E.C., Costa G. and Vieira T.C., 2007. Cherubism: Clinicoradiographic Features, Treatment, and Long-Term Follow-Up of 8 Cases, *J. Oral Maxillofacial Surgery*, **65**:517-522.