

AGENESIS OF LATERAL INCISORS: TREATMENT OPTIONS AND CASE REPORT**VIPUL KUMAR SHARMA^{a1}, SANDEEP KUMAR^b, KIRTI YADAV^c AND T.P. CHATURVEDI^d**^{abd}Department of Orthodontics and Dentofacial Orthopaedics, FODS, IMS, BHU, Varanasi, Uttar Pradesh, India^cDepartment of Periodontology, FODS, KGMU, Lucknow, Uttar Pradesh, India**ABSTRACT**

Agnesis of one or more teeth constitutes one of the most common developmental anomalies in man. Maxillary lateral incisors are the most frequently missing teeth when only one or two teeth are absent, whereas second premolars are the most frequently missing teeth when more than two teeth are absent. Managing patients with congenitally missing maxillary lateral incisors raises several important issues involving the amount of space, patient's age, type of malocclusion, treatment duration, tooth display when smiling and particularly, the condition, shape and size of the canine and condition of the adjacent teeth. There are two treatment options: 1) Canine substitution followed by space closure. 2) Space creation for missing lateral incisors followed by prosthetic replacement. Both treatment options have advantages and disadvantages. Here, we are going to present treatment of a rare case of missing bilateral maxillary and mandibular lateral incisors.

KEYWORDS: Agnesis of Lateral Incisors, Prosthetic Replacement, Dental Implant

Agnesis of one or more teeth constitutes one of the most common developmental anomalies in man. The reported incidence of permanent tooth agnesis varies from 1.6 to 9.6%, excluding third molars, which occurs in 20% of the population (Graber, 1978). Maxillary lateral incisors are the most frequently missing teeth when only one or two teeth are absent, whereas second premolars are the most frequently missing teeth when more than two teeth are absent (Muller et al, 1970). Females are more affected than males. Aetiologies vary and include congenital absence, trauma, decay, and more rarely, the surgical management of jaw tumours. Maxillary lateral incisors show the highest genetic component of variability in the general population, whereas the smallest genetic influence on size of an anterior tooth is seen in the canine (Goose, 1976). Managing patients with congenitally missing maxillary lateral incisors raises several important issues involving the amount of space, patient's age, type of malocclusion, treatment duration, tooth display when smiling and particularly, the condition, shape and size of the canine and condition of the adjacent teeth. Although canine substitution, restorative replacement with bridgework, and even autotransplantation offer options for replacement, dental implants remain a viable technique (Kokich and Kinzer, 2005). Here, we are going to present treatment of a rare case of missing bilateral maxillary and mandibular lateral incisors.

CASE REPORT

An eighteen years old female presented to the Department of Orthodontics and Dentofacial Orthopaedics with a chief complaint of spacing in upper and lower anteriors. Extraoral examination showed pleasing facial

profile with competent lips. Intraoral examination showed Angle's Class I molar relationship, 2 mm of overjet and overbite with absence of maxillary and mandibular lateral incisors. After radiographic examination (orthopantomogram), diagnosis of agnesis of lateral incisors was made. Intraoral examination of her father also revealed the absence of maxillary lateral incisors. (Figure 1) It confirms etiology of familial origin.

Treatment Planning and Treatment Progress

There were two treatment options: 1) Canine substitution followed by space closure. 2) Space creation for missing lateral incisors followed by prosthetic replacement. Diagnostic set-up was made and second treatment option was selected, not to compromise facial profile. Treatment progressed as alignment and leveling with 0.016 NiTi followed by 0.017x0.025 NiTi and 0.019x0.025 stainless steel for 5 months. Open coil spring (0.010"x0.030" NiTi) was compressed to create space for missing lateral incisors in both the arches for 3 months. (Figure 2) After space creation, Dentscan was taken to determine the height and width of the bone for dental implant. (Figure 3) The measurements of bone indicated use of narrow diameter implants (2.8x10) to restore missing maxillary lateral incisors. There was inadequate bone to place dental implant for missing mandibular lateral incisors. So, Single-retainer cantilever zirconia-based All-ceramic resin-bonded fixed partial denture (CRBFPD) was fabricated and adhesively bonded to the abutment teeth. (Figure 4) After 12 months, good esthetic smile with class I canine relation was achieved.

¹Corresponding author

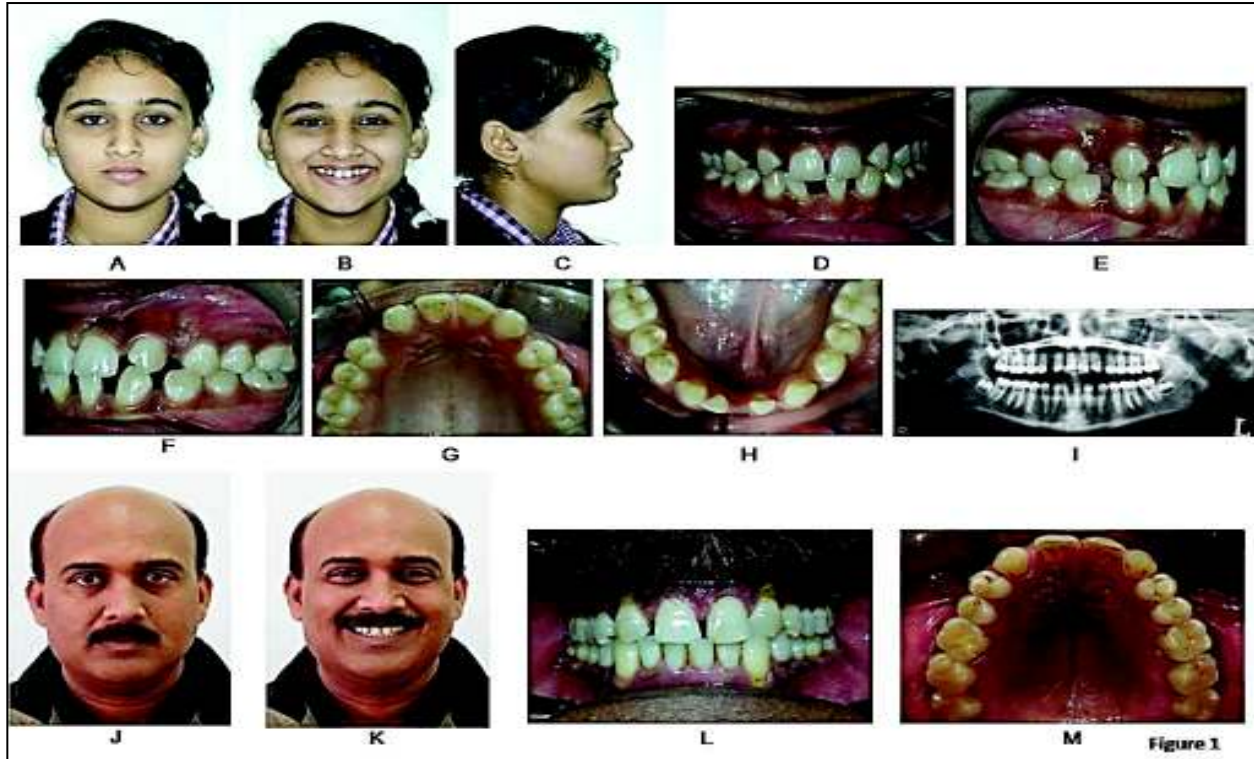


Figure 1: Pretreatment extraoral and intraoral photographs (A-H), Orthopantomogram (I) and extraoral and intraoral photographs of Patient's father (J-M)

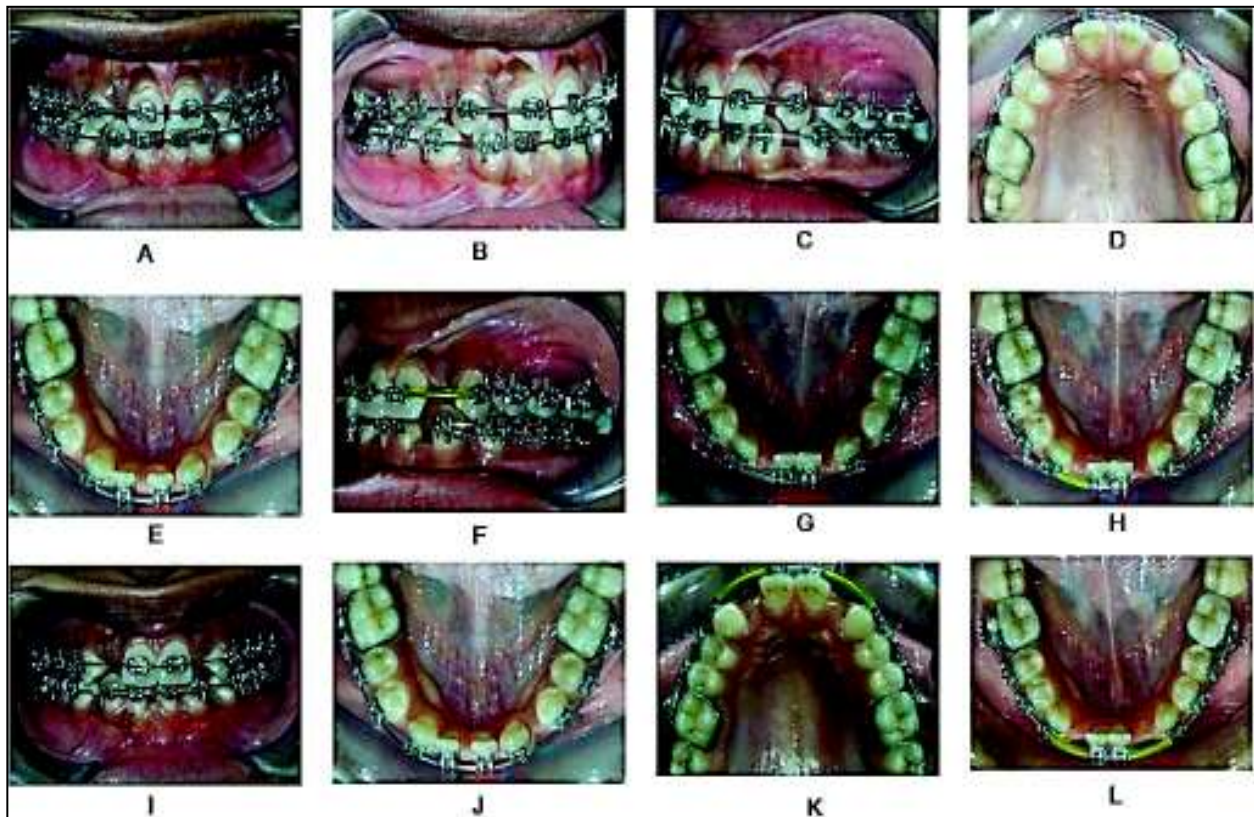


Figure 2: Space creation (A-L)

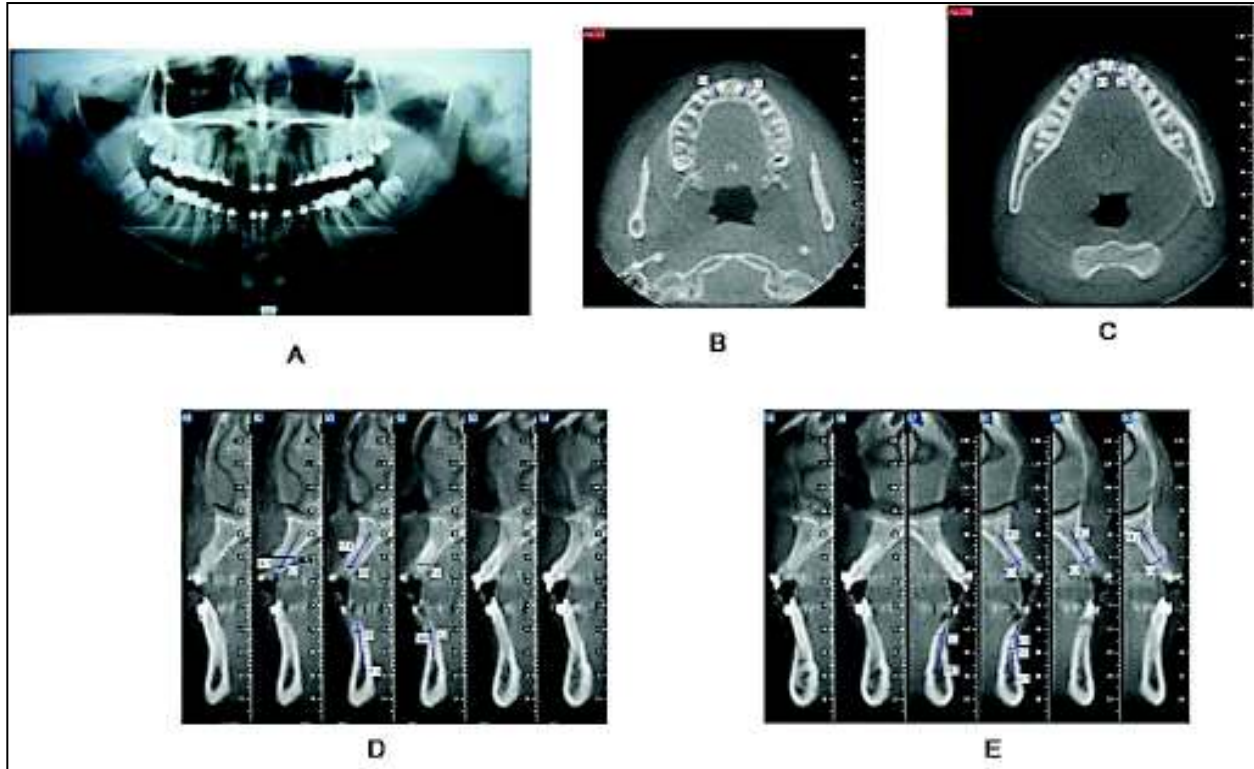


Figure 3: Midstage orthopantomogram (A) and Dentascan (B-E)

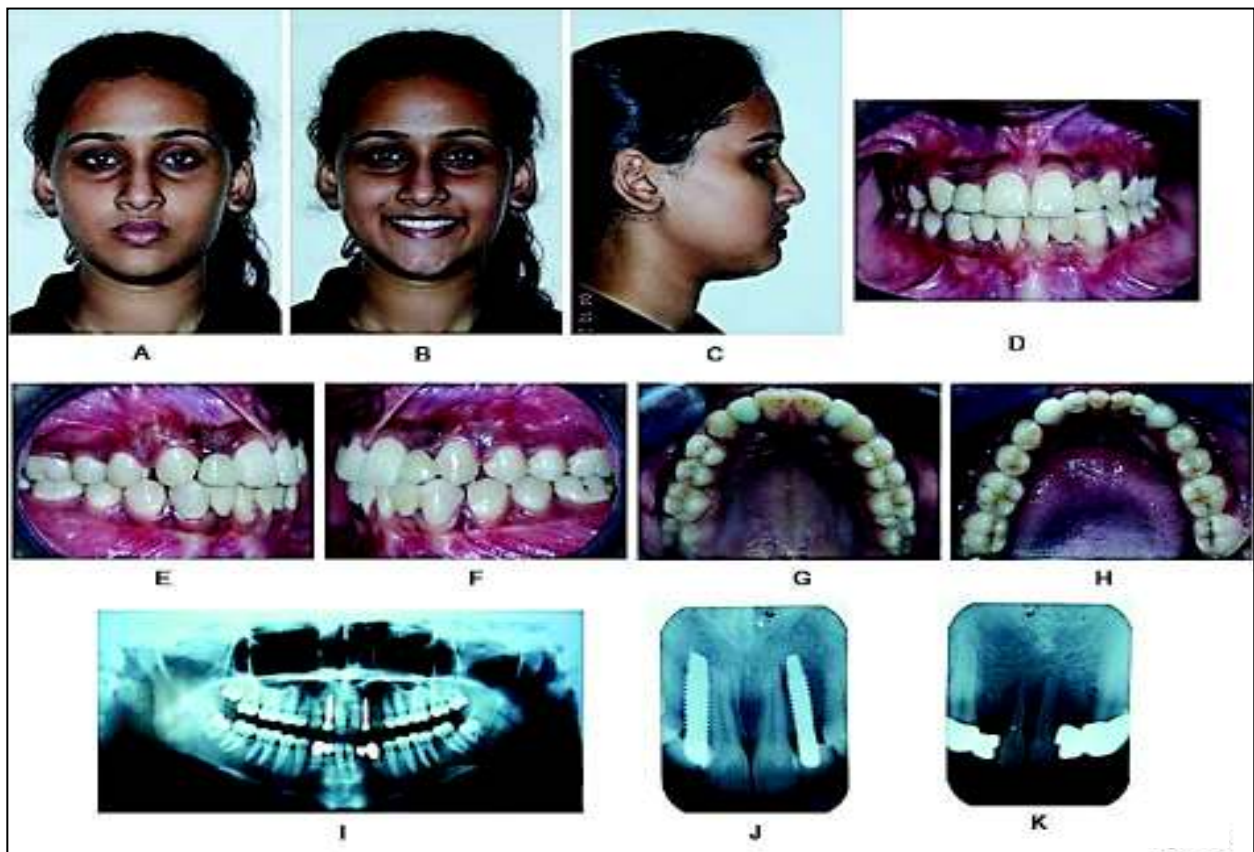


Figure 4: Post-treatment photographs (A-H) and radiographs (I-K)

DISCUSSION

Since, lateral incisors play very important role in smile design, including smile arch, lip line and type I gingival height, management of missing maxillary lateral incisors requires thorough treatment planning and an interdisciplinary approach. Both treatment options have advantages and disadvantages. Space closure-canine substitution is usually indicated in cases with smaller, shorter, less angular canines having narrow mesio-distal widths at the cemento-enamel junction, slight protrusive profile, cases requiring extraction in mandibular arch due to arch length discrepancy (Zachrisson ET AL, 2011). Canines with darker shade and normal dimension limit substitution. Extensive remodelling of the teeth might involve such complications as the development of an increased sensitivity to hot and cold, dental pain, tooth discoloration due to dentin exposure or pulp obliteration, and dental caries (Thordarson et al, 1991). Adult patients with retrusive profile with class I canine relation are better candidates for prosthetic replacement. Restorative treatment alternatives can be divided into 2 categories: a single-tooth implant and a tooth-supported restoration. The 3 types of tooth supported restorations available today are a resin bonded fixed partial denture (FPD), a cantilevered FPD, and a conventional full-coverage FPD. Implants are often perceived as the most “conservative” approach because adjacent teeth do not require any modification maintaining the morphology of the canine and first premolar (Kokich and Kinzer, 2005). Determining the amount of space needed is a critical first step. If the contralateral tooth is present, determining the space between the teeth requires measurement of the contralateral tooth. Unfortunately, in many cases of congenital missing laterals, both are missing. In these cases, alternative methods, such as Bolton analysis, the Golden proportion, or diagnostic wax-up can provide the orthodontist with valuable input on the proper dimensions (Kokich and Kinzer, part II-III, 2005). Although some authors have suggested 1 mm of bone is adequate, ideally at least 1.5 mm is required at the coronal portion between adjacent teeth and implant for periodontal health and esthetics. If amount of bone is less than 1.5 mm, results in apical migration of the papillary tissue, leading to open gingival embrasures and lack of gingival scallop (Krasnig and Fickl, 2011). Changes in the dental arch and facial skeleton with age may lead to implant submergence and displacement (Thilander, 2009). The gold standard of skeletal maturation, however, remains 2 superimposed cephalometric films taken 1 year apart showing no change.

Vertical changes of 0.12-1.86 mm per year have been demonstrated in adults up to age 40-55 years (Bernard et al, 2004). A 3-dimensional radiography (CBCT/Dentscan) can provide more information regarding the relationship of the adjacent roots and implants. The ideal patient for a zirconia CRBFPD is a nonbruxer who has abutment teeth that are immobile and upright and a shallow overbite that will allow maximum enamel surface area for adhesion (Kokich et al, 2011). Contraindications include a deep overbite, proclined teeth, mobile teeth, or a history of bruxism (Rosentritt et al, 2009).

CONCLUSION

The treatment of congenitally missing maxillary lateral incisors is complex and involves a multidisciplinary approach. Formulating an appropriate treatment plan for each patient should be taken into consideration. Generally, the treatment of choice should be the least invasive option that satisfies the expected esthetic and functional objectives. Dental implants have become a well-known option to most patients and families, and are often seen by family and clinicians as an ideal replacement

REFERENCES

- Bernard J.P., Schatz J.P. and Christou P., 2004. Long-term vertical changes of the anterior maxillary teeth adjacent to single implants in young and mature adults. *J. Clin Periodontal*, **31**:1024-1028.
- Goose D.H., 1967. Preliminary study of tooth size in families. *J. Dent Res.*, **46**:959-62.
- Graber L.W., 1978. Congenital absence of teeth: a review with emphasis on inheritance pattern. *J Am Dent Assoc*, **96**:266-75.
- Kokich V.O. and Kinzer G.A., 2005. Managing congenitally missing lateral incisors. Part II: Tooth-supported restorations. *J. Esthet Restorative Dent*, **17**:76-84.
- Kokich V.O. and Kinzer G.A., 2005. Managing congenitally missing lateral incisors. Part III: Single-tooth implants. *J Esthet Restorative Dent*, **17**:202-210.
- Kokich V.O., Kinzer G.A. and Janakievski J., 2011. Congenitally missing maxillary lateral incisors: Restorative replacement. *Am. J. Orthod Dentofacial Orthop*, **139**:435-445.

- Krasnig M. and Fickl S., 2011. Congenitally missing lateral incisors-a comparison between restorative, implant and orthodontic approaches. *Dent Clin North Am.*, **5**:283-299.
- Muller T.P., Hill I.N., Peterson A.C. and Blayney JR. A., 1970 survey of congenitally missing permanent teeth. *J Am Dent Assoc*, **81**:101-7.
- Rosentritt M., Ries S., Kolbeck C., Westphal M., Richter E.J. and Handel G., 2009. Fracture characteristics of anterior resin-bonded zirconia-fixed partial dentures. *Clin Oral Investig*, **13**:453-457.
- Thilander B., 2009. Dentoalveolar development in subjects with normal occlusion. A longitudinal study between the ages of 5 and 31 years. *Eur J Orthod*, **31**:109-120.
- Thordarson A., Zachrisson B.U. and Mjor I.A., 1991. Remodelling of canines to the shape of lateral incisors by grinding: a long term clinical and radiographic evaluation. *Am J Orthod Dentofacial Orthop*, **100**:123-132.
- Zachrisson B.U., Rosa M. and Toreskog S., 2011. Congenitally missing maxillary lateral incisors: Canine substitution. *Am J Orthod Dentofacial Orthop*, **139**(4): 434-444.

