

## ROLE OF B-SCAN ULTRASONOGRAPHY IN DETECTING OBSCURED OCULAR ABNORMALITIES IN MATURE TRAUMATIC CATARACT

ASIM NAIK<sup>a1</sup>, SHASHIPRABHA PRASAD<sup>b</sup> AND RENU MAGDUM<sup>c</sup>

<sup>abc</sup>Professor & Head, Department of Ophthalmology, Dr. D.Y. Patil Medical College, Pune, Maharashtra, India

### ABSTRACT

Trauma to eye is one of the common ocular health problems worldwide. Various studies had reported ocular trauma as cause of monocular blindness. Ocular trauma is higher among young generation due to their involvement in various activities like sports, accidents. With the aim of determining the role of B-scan ultrasonography in evaluation of obscured ocular abnormalities in mature traumatic cataract, a prospective cross sectional study conducted among patients with history of mature traumatic cataract. Based on inclusion criteria, total 35 patients were enrolled into study. Out of total, 68.6% were males with male female ratio of 2.2:1. Mean age of the patients was 33.09±18.6 years. Mean IOP of right eye was 14.4±5.5 mmHg and Left eye was 15.8±6.2 mmHg. Commonest causes of injury were cricket ball (20%), punch (17.1%), broomstick (8.6%), wooden piece (8.6%) and gym plate (5.7%). On B scan ultrasonography, 17.1% had total retinal detachment, 8.6% had posterior vitreous detachment, 2.7% had retinal detachment with vitreous hemorrhage and others. Upon concluding, B-scan ultrasound found to be an important diagnostic tool for detection of hidden posterior segment lesions and can performed routinely in pre-operative cataract patients with hazy or opaque media. It might help in deciding line of treatment.

**KEYWORDS:** Ultrasonography, Ocular Abnormalities, Traumatic Cataract

From ancient times, eye injuries have been known. Eye has protective bony wall and lids to cover the eye to protect it from injury but still, it is expose to all types of trauma. Ocular trauma is one of the cause of blindness in about half a million people worldwide, and many more have grieved partial loss of sight. Trauma is frequently the main cause of unilateral loss of vision, particularly in developing countries. In developing countries, superficial corneal trauma in agricultural work, often leading to rapidly progressing corneal ulceration and visual loss. Ocular trauma is a significant but avoidable cause of blindness worldwide (Pandita and Merriman, 2012). Thylefors (1992) reported in their study that worldwide 1.6 million people are blind secondary to ocular injuries, 2.3 million with low visual acuity bilaterally and 19 million with unilateral blindness or low vision. In many studies, it had reported that up to 60.5% of cases of ocular injury end up with significant visual loss and higher rates reported among men under age of 30 years (Tielsch and Parver, 1989). In most of descriptive and controlled epidemiologic studies, they had reported high rates of ocular injury in young adults. This will directly or indirectly leads to significant loss of time and high DALY, which is responsible for high economic burdens as, linked to other healthy people because of time lost from work or school. (Kalyanpad and Shinde, 2014)

Position of ocular injuries in causativeness of blindness has been issue of enormous importance, will remain due to the rapid industrialization, and mechanized farming, which is coining up in our country (Rajani, 2016). The lens is the main stay for normal functioning of the optical system of the eye that includes the transparency and integrity. Cataract formation starts taking place in the lens if there is any damage to it. Traumatic cataract occurs when lens damaged by blunt and penetrating trauma. Other ocular structures also injured with it. Thus, visual rehabilitation is one of the most important factors as amblyopia in children and virtual incapacitation in adults that can prevent.

Smaller tear in anterior capsule was self-seals but it leaving behind a focal opacity while the larger ones result in cataractous changes in the entire lens. Cataract formation also occurs even if the capsular integrity was intact after trauma or subsequent inflammation. Lens damage leads peripheral epithelial cells to undergo fibrous metaplasia creating anterior fibrous plaques causing anterior subcapsular cataracts. Blunt trauma cataracts have rosette or flower pattern. It corresponds to sectors of cortical opacity (Macewen, 1989). Commonest associations of trauma also include posterior sub capsular cataract (Wong *et al.*, 2002). For good surgical care, it was essential to evaluate the posterior segments accurately in opaque media. In patients

with dense cataracts, the posterior segment was not accessible to direct and indirect ophthalmoscopy and so adequate assessment of the posterior segment to exclude abnormalities becomes a difficult task. There was risk of poor visual prognosis in patients with cataracts who might also have co-existing posterior segment abnormalities. In these situations, B Scan Ultrasonography provides a method of assessing the structural changes in the posterior segment in these patients. (Wong *et al.*, 2002)

Various evaluation technique like clinical examination, slit lamp examination, ophthalmoscopy and ultrasound bio microscopy with frequency of 50 MHz are better diagnostic tools for cornea, anterior chamber, lens and posterior chamber, than ultrasonography (Dannenberg *et al.*, 1992) (Tielsch and Parver, 1989). Previously, ophthalmologists use a dedicated equipment for ocular ultrasonography (Thylefors, 1992). However, with change of times, general equipment for ultrasonography with high frequency small part probes are gradually becoming popular amongst the radiologists. The portion of the fluid in the eyeball makes the examination with the ultrasonography suitable in case of opaque media. Ultrasonography is the cornerstone of posterior segment images of the eye. Prior to vitrectomy it is the most proficient investigation. The prime techniques for diagnosis of posterior segment lesions are A scan and B scan. Shape and topographic relations of lesions of posterior segment are better understood with B (Brightness) mode. For detection of any posterior segment anomalies, B scan is very useful as it provides cross sectional display. (Mohamad *et al.*, 1383) Retinal detachment, vitreous hemorrhage, intra ocular foreign body, neoplasia and posterior vitreous detachment are the most frequent findings, in case of both blunt and penetrating trauma or without trauma, recorded on B Scan (Krishnan and Sreenivasan, 1988). Hence, the current study planned at our tertiary care center to document the role of B Scan ultrasonography in evaluation of obscured ocular abnormalities in Mature Traumatic Cataract and correlate the ultrasonography finding with ocular abnormalities.

## METHODOLOGY

A hospital based prospective cross sectional study conducted with 35 patients in Dr. D. Y. Patil Medical College, Hospital and Research Centre, Pimpri Pune to analyze role of B-scan ultrasonography in evaluation of

obscured ocular abnormalities in mature traumatic cataract for the duration of 2 years from September-2016 to August-2018. All the patients who were willing to give written consent, enrolled into current study. Patients with an active ocular surface infection, with open globe injury prior to repair and who were not willing to participate, were excluded from study. The study initiated only after the review and formal approval of the study synopsis by the Institutional Ethics committee (IEC) Patient explained about the study and outcomes of study. Patient assured that his/her reports kept confidential.

Sample size calculated using the formula:  $n = [Z^2 p(1-p)]/d^2$ , where: Z = table value of alpha error from Standard Normal Distribution table (0.95) Power (p) = 80%, Precision error of estimation (d) = 0.65.  $n = [0.95 \times 0.95 \times 0.8 (0.2)] / 0.65 \times 0.65 = 34.18$ . Hence, a sample size of 35 patients was considered adequate for current study.

Prior to examination of patients, written and informed consent obtained from all patients. Semi-structured questionnaire filled and all patients undergoing a complete ocular examination. Vision were assessed by Snellen's chart, then slit lamp examination was done, fundus examination was carried out with 90D lens & indirect ophthalmoscope, and intraocular pressure were recorded by Goldmann Applanation Tonometer. Ultrasound examination done with standard USG machine (CAS-2000B) equipped with a real-time high-frequency probe with the contact method. The probe with 10 MHz placed over the closed eyelid after application of coupling gel. With use of 60-degree mechanic sector scan, depth up to  $\geq 50$  mm assessed. Images stored in 10 frames Dynamic playback: 100 frames Accuracy: Axial 0.2mm, Lateral less than 0.5 mm Grayscale: Levels 256 with display mode: B, B+B, B+A. After data collection, all the data entered in MS Excel spreadsheet and analyzed with the help of Open Epi and SPSS V. 20(available free). Categorical data explained with frequencies and percentage. Continuous variable explained with mean and SD. Bar diagram used to explained categorical data. Study approved from ethics committee, Dr. D. Y. Patil Medical College, Hospital and Research Centre, Pimpri, Pune.

**RESULTS**

Mean age of study participants was 33.09±18.6 years. Out of total, 45.7% participants were belongs to age group 11 to 30 years, 45.7% participants more than 30 years of age group and 8.6% participants of less than 10 years. Majority of study participants were males 68.6% with male-female ratio of 2.2:2. All cases had head posture centrally (35/35). Present study reported cricket ball (20%) as most common cause of injury followed by punch (17.1%), broomstick (8.6%), wooden piece (8.6%), gym plate (5.7%), pencil (5.7%), stick (5.7%) and others. Most common symptoms were DOV, pain, watering and redness of eyes that found in 74.3%, while 25.7% had DOV, pain and watering in eyes.

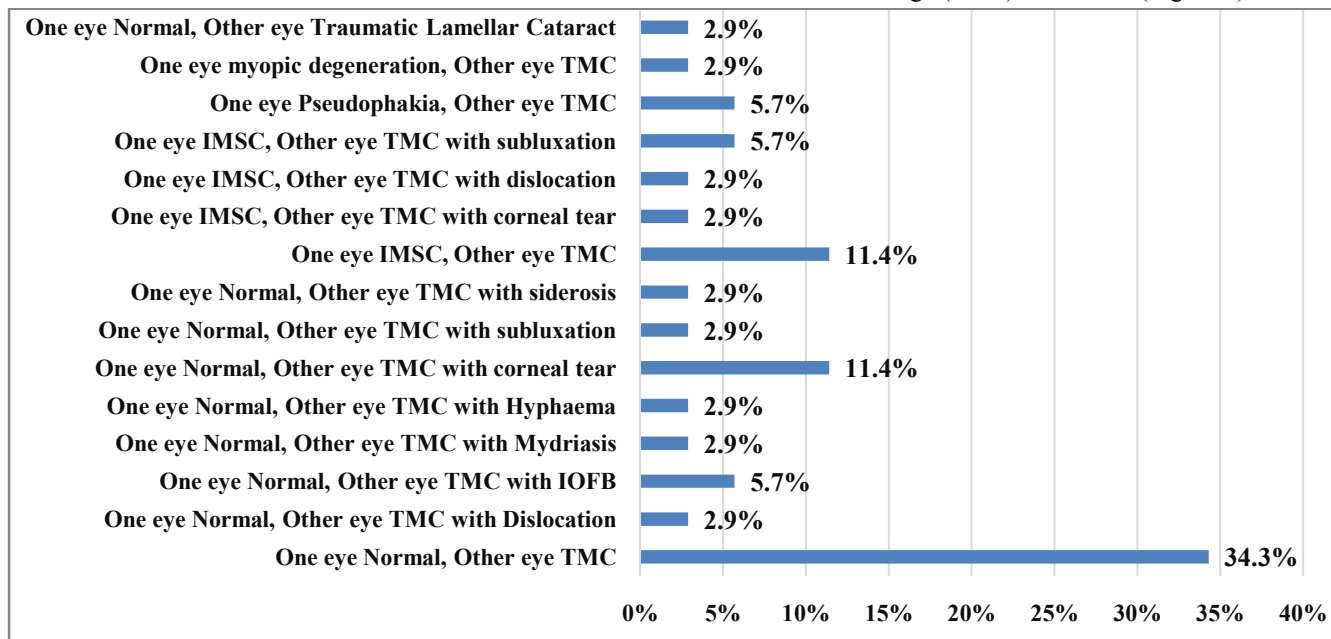
In current study, majority of the patients' vision in right eye was PL+ PR accurate (37.1%), followed by 6/6(28.6%), PL+ PR Inaccurate (14.3%), 6/12(8.6%), 6/36(5.7%) and remaining. BCVA (best corrected visual acuity) reported no improvement in 80% patient, 6/6 (8.6%) and 6/9 (5.7%) and 6/12 (5.7%) in right eye. Moreover, in left eye, 42.9% had vision PL+ PR Accurate, followed by 6/6 vision (31.4%), 6/12 (5.7%), 6/18 (5.7%) and 2.9% one for each patient had 6/9,6/36, 6/60, PL+ PR Inaccurate and No PL. While BCVA in left eye, no improvement in 80%

patients, 8.6% had 6/6, 5.7% had 6/9, 2.9% for each 6/18 and 6/24.

Near vision in all patients had found that, 28.6% cases had N6 vision followed by N18 in 8.6% cases, N10 in 5.7% cases, while 51.4% had not recorded near vision of right eye. In addition, in left eye, 40% cases had N6 vision, followed by N12 in 5.7% cases, N10 in 2.9% cases, while 48.6% had no recorded near vision of left eye.

Mean IOP of right eye was 14.4±5.5 mmHg and mean IOP of left eye was 15.77±6.2 mmHg. On slit lamp examination, Majority of the patients (34.3% had one normal eye and other eye had Traumatic Mature Cataract (TMC), followed by 11.4% (One normal eye, other eye TMC with corneal tear), 11.4% (One eye had IMSC {Immature senile cataract}, other eye TMC), 5.7% had (One normal eye, other eye TMC with IOFB), 5.7% (One eye IMSC, other eye TMC with subluxation), 5.7% (One pseudophakia eye, other eye TMC) and others (Figure 1).

In current study, most common finding on B scan ultrasonography was intact posterior chamber with clear vitreous and attached Retina (45.7%), followed by total retinal detachment (17.1%), only PVD (posterior vitreous detachment, 8.6%), retinal detachment with Vitreous Hemorrhage (5.7%) and others (Figure 2).



**Figure 1: Distribution of patients based on Slit lamp Examination findings (n=35)**

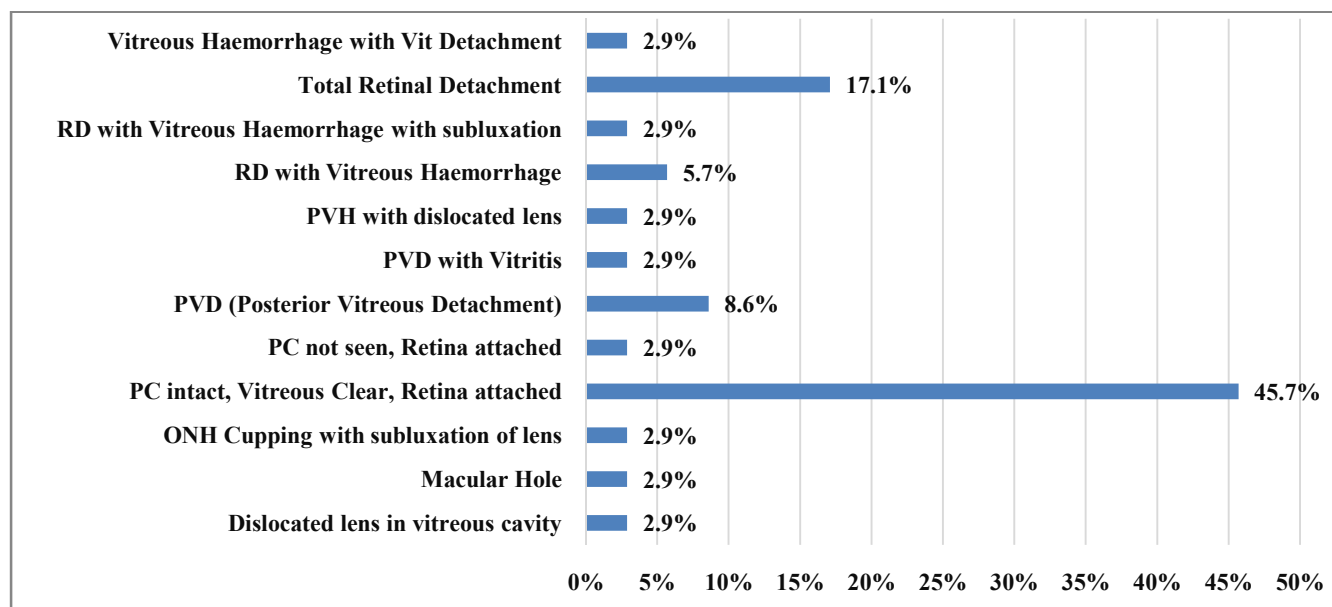


Figure 2: Distribution of all patients based on B-scan Ultrasonography findings (n=35)

**DISCUSSION**

Present cross sectional study conducted at tertiary care center for documenting role of B-scan ultrasonography for the evaluation of obscured ocular abnormalities in mature traumatic cataract and co-relate its findings with ocular abnormality. Traumatic cataract was more common in younger age group due to more involvement in outdoor games and activities and thus having more chances of trauma.

In current study, majority of the ocular trauma was occurs in younger age groups with mean age of 33.09±18.6 years. Male suffers more compare to females with male – female ratio of 2.2:1. Similarly other study by Thyleforset al had found that ocular trauma more commonly seen in males (M:F ratio 4:1) and at a much younger age (average age, 36 years) comparing to females (average age, 73 years) (Thylefors, 1992). Similarly, Jain et al who had evaluated posterior segment lesions among pre-operative cataract patients, found higher male female ratio 1.1:1 (Jain et al., 2017). Rai et al., (2007) also found higher male-female ratio of 2.9:1 in penetrating ocular trauma and 3.2:1 in blunt ocular trauma.

Dana et al reported that cornea and corneoscleral regions were the most common sites of injury due to the

greater exposure of these structures to impact. The most common causes of ocular injuries were either work related or chance events. Cataracts occur because of ocular trauma (Mohamad et al., 1383). Present study reported commonest causes of ocular trauma were cricket ball (20%), punch (17.1%), broomstick (8.6%), wooden piece (8.6%) and others.

Evaluation of visual outcomes in cataracts, both traumatic and senile was similar but Visual prognosis was different, as the injury that produced to the other structures affects the visual prognosis in traumatic cataracts. Opacification of Crystalline lens occurs either suddenly after trauma or might also not occur even after years (Dannenberg et al., 1992). The extent and the nature of the trauma decides the type of cataract formation. Though there was no standard morphological classification for the cataract formation due to penetrating injuries but it was directly related to the size of tear in the lens capsule (Liggett et al., 1990).

Qureshi et al found in their study that 9.5% cases were of post-traumatic cataract and 90.5% were non-traumatic cataract. In the non-traumatic cataract group, majorities (72.16%) were in the range of 50 to 69 years of age with mean (SD) age of 54 (8.25) years, where majority of patients were females (42.1%) compared to males

(30.04%). In traumatic cataract group, injuries were mild, blunt and penetrating in nature, most of the patients (49.29%) were in the range of 10 to 19 years, the mean (SD) age was 13.7 (2.73) years, majority of patients (40.84%) were males compare to females (8.45%) (Qureshi and Laghari, 2010). Present study and other two studies reported similar finding. (Jain *et al.*, 2017) (Rai *et al.*, 2007) (Qureshi and Laghari, 2010)

Present study reported cricket ball (20%) as most common cause of injury followed by punch (17.1%), broomstick (8.6%), wooden piece (8.6%), gym plate (5.7%), pencil (5.7%), stick (5.7%) and others. Rai *et al.*, reported commonest causes of ocular injury were assault by fist/wooden stick (23.8%), Cricket Ball (19%), Gulli Danda (Tip Cat, 14.3%), stone (14.3%), Buckle of belt (9.1%), plastic toy (9.1%), corner of door (9.1%) (Rai *et al.*, 2007). Most common symptoms were DOV, pain, watering and redness of eyes that found in 74.3%, while 25.7% had DOV, pain and watering in eyes. Similar complaints were recorded in a study conducted by Jain *et al.*, (2017).

In current study slit lamp examination found 34.3% patients had one normal eye & other eye had Traumatic Mature Cataract (TMC), 11.4% had one normal eye & other eye TMC with corneal tear, 11.4% had one eye had IMSC & other eye TMC, 5.7% had one normal eye & other eye TMC with IOFB, 5.7% had one eye IMSC & other eye TMC with subluxation, 5.7% had one pseudophakia eye & other TMC eye and others (Chart 1). These findings were consistent with the studies of Qureshi and Laghari, 2010 and Jain *et al.*, 2017.

In current study, most common finding on B scan ultrasonography was intact posterior chamber with clear vitreous and attached Retina (45.7%), followed by total retinal detachment (17.1%), only PVD (posterior vitreous detachment, 8.6%), retinal detachment with Vitreous Hemorrhage (5.7%) and others (Chart 2). On B-scan ultrasound, Jain *et al.* had found posterior segment pathology in 33.3% traumatic patients, which were Retinal Detachment (11.1%), Vitreous Haemorrhage (5.6%) and Intraocular Foreign Body (16.7%) (Jain *et al.*, 2017). Mendes *et al.*, (2009) in their retrospective study of assessing Ultrasonographic findings of cataract detection had reported medium to profound opacity of the lens in 77.5% patients presented with vitreous detachment. In

30.1% of the patients, the ultrasound revealed eye abnormalities that could compromise the function of the eye after surgery. The most common of these abnormalities was vitreous opacities (12.1%) followed by retinal detachment (9.3%).

Anteby *et al.*, (1998) observed dense cataract in non-traumatic cataract group reported retinal detachment in 3.9%, vitreous hemorrhage in 2.5% and posterior staphyloma 7.6%. In traumatic cataract group retinal detachment observed was 14.8%, vitreous hemorrhage 3.7% and intraocular foreign body in 7.4%. Qureshi and Laghari, 2010 observed retinal detachment in 1.47%, vitreous hemorrhage in 1.91%, posterior vitreous detachment in 1.03%, posterior staphyloma in 1.32%, and no pathology in 93% patients. In traumatic cataract patient group, retinal detachment observed in 21.22% patients, vitreous hemorrhage in 15.49%, posterior vitreous detachment in 9.86%, intraocular foreign body in 8.45% and no pathology in 45% patients.

## CONCLUSION

Two-dimensional B-scan ultrasound is one of the main diagnostic tools for the detection of hidden posterior segment lesions and can be performed routinely in pre-operative cataract patients with hazy or opaque media. It would help in planning for surgical intervention. In cases, where a two dimensional B-scan is not sufficient or helpful, a three dimensional ultrasound would be justified.

## REFERENCES

- Thylefors B., 1992. Epidemiological patterns of ocular trauma. Aust N. Z. J. Ophthalmol, **20**(2):95–8.
- Pandita A. and Merriman M., 2012. Ocular trauma epidemiology: 10-year retrospective study. J. New Zeal Med. Assoc. NZMJ., **125**(1348):8716.
- Tielsch J.M. and Parver L.S.B., 1989. Time trends in the incidence of hospitalised ocular trauma. Arch Ophthalmology, **107**:519–23.
- Kalyanpad P.N. and Shinde C.A., 2014. Incidence of traumatic cataract in ocular injuries : a prospective observational study. Int. J. Recent Trends Sci. Technol., **12**:110–3.

- Rajani P., 2016. A study on clinical profile of mechanical ocular injuries Dr. World J. Pharm Sci., **4**(9):449-52.
- Macewen C.J., 1989. Eye injuries: A prospective survey of 5671 cases. Br J. Ophthalmol, **73**(11):888-94.
- Wong T.Y., Klein B.E.K., Klein S.C.T.R., 2002. Relation of ocular trauma to cortical, nuclear and Study. Br J. Ophthalmol, **88**:152-5.
- Dannenberg A.L., Parver L.M., Brechner R.J. and Khoo L., 1992. Penetrating Eye Injuries in the Workplace: The National Eye Trauma System Registry. Arch Ophthalmol, **110**(6):843-8.
- Mohamad R.D., James M.T., Cheryl E., Ellen J., Jeanne M. and Santoli H.R., 1383. Visual impairment in a rural appalachian community: Prevalnce and causes. J Am Med Assoc., **264**(18):2400-5.
- Krishnan M. and Sreenivasan R., 1988. Ocular injuries in union territory of Pondicherry--clinical presentation. Indian J. Ophthalmol, **36**(2):82-5.
- Jain A., Gauba N., Inderjit and Sohan H., 2017. Role of B-Scan in Cataract Patients. Indian J. Appl. Radiol., **3**(1):110.
- Rai P., Imtiaz S., Shah A., Cheema A.M., Niazi H. and Sidiqi S.J., 2007. Usefulness of B-Scan Ultrasonography in Ocular Trauma. Orig Artic Pak J. Ophthalmol, **23**(3):136-43.
- Liggett P.E., Pince K.J., Barlow W., Ragen M. and Ryan S.J., 1990. Ocular Trauma in an Urban Population: Review of 1132 Cases. Ophthalmology, **97**(5):581-4.
- Qureshi M.A. and Laghari K., 2010. Role of B-scan ultrasonography in pre-operative cataract patients. Int. J. Health Sci. (Qassim), **4**(1):31-7.
- Mendes M.H., Betinjane A.J., Cavalcante A. de S., Cheng C.Te and Kara-José N., 2009. Ultrasonographic findings in patients examined in cataract detection-andtreatment campaigns: a retrospective study. Clinics., **64**(7).
- Anteby I.I., Blumenthal E.Z., Zamir E. and Waindim P., 1998 The role of preoperative ultrasonography for patients with dense cataract: a retrospective study of 509 cases. Ophthalmic Surg. Lasers, **29**:114-8.