

## ROLE OF SOME ANTIOXIDANTS ON MERCURY CHLORIDE INDUCED SPERMATOGENESIS IN SWISS ALBINO MICE DURING PRE PUBERTAL PHASE OF LIFE

DUGESH NANDINI SHARMA<sup>a1</sup> AND LATA BHATTACHARYA<sup>b</sup>

School of Studies in Zoology and Biotechnology, Vikram University, Ujjain, M.P., India

<sup>a</sup>E-mail: dr.durgeshnandini@rediffmail.com

<sup>b</sup>E-mail: dr.latabhattacharya@rediffmail.com

### ABSTRACT

The present study was undertaken to investigate the ability of antioxidants (Vitamin C and E) to protect against mercuric chloride induced testicular toxicity in male mice during pre pubertal phase of life. A sublethal chronic exposure (0.5 ml/day of 0.5 ppm aqueous HgCl<sub>2</sub>) resulted in regressed histological properties of the testis. The changes observed were broken and detached tunica albuginea, abnormal configuration of seminiferous tubules, deformed primary and secondary spermatocytes, hypertrophy and vacuolization in Leyding cells and Sertoli cells. The diameter of different spermatogenic cells were significantly (P<0.001) decreased. These changes were ameliorated with the administration of vitamin C and E. The results of our study suggested that antioxidant vitamin C and vitamin E exert significant protection against histological damage of testes induced by mercury and provide a strong evidence for the beneficial role of antioxidant vitamins in prevention of mercury toxicity.

**KEYWORDS:** Hypertrophy, HgCl<sub>2</sub>, antioxidant, vitamin C, vitamin E

The environmental contamination due to heavy metal compounds such as mercuric chloride causes highly toxic effects on reproductive tissues of mice. It is now evident that toxic substance like heavy metals and their compounds released into the environment and affect the reproductive processes and fertility of the animals. Mercuric chloride is a cumulative poison and is considered as a direct-acting toxicant. Kect et al., (1993) reported elevated testicular mercury in an infertile man employed in the chloralkali industry. Decrements in sperm count, motility and morphology have been reported in methyl mercury exposed monkeys (Mohamed et al.,1987). Rao et al., (1987) reported changes in hydrolytic enzyme of rat testicular tissue due to HgCl<sub>2</sub> intoxication, while Ernst et al. (1991) investigated ultrastructural demonstration of mercury in Sertoli and Leydig cells of rat testis following methyl mercuric chloride treatment.

Vitamin C and E are well recognized antioxidant vitamins that exert a precise protective role in lead induced organ toxicity (Banu and Sharma, 2005). Patil and Rao (1999) reported that vitamin E inhibits oxidative damage in the liver and other tissues caused by mercury and cadmium intoxication, while Acharya et al. (2003) investigated effects of vitamin C against lead acetate induced spermatogenesis in Swiss mice. The present study has been undertaken to assess the mercury induced oxidative damage

on male germinal cells and their protection by antioxidants such as vitamin C and E using Swiss mice as an experimental model.

### MATERIALS AND METHODS

Male Swiss albino mice procured from a live animal supply farm (Veterinary College, Mhow) and were employed as test animals in the present study. They were maintained under standard laboratory condition and providing them balance diet and water *ad libitum* daily.

#### Experimental Protocol

Immature male mice group (pre pubertal phase, 28, 35 and 42 days old mice) were divided into four groups viz. A, B, C and D. 18 animals were kept in each group. Observations were taken after 7, 14 and 21 days of inoculation.

**Group A (Control group):** Providing standard food and water.

**Group B (Experimental group):** Treated with 0.5 ml/ day of 0.5 ppm aqueous HgCl<sub>2</sub>.

**Group C (Recovery I):** Treated with HgCl<sub>2</sub> + Vitamin C (0.5 ml/day + 200 mg/kg/day respectively)

**Group D (Recovery II):** Treated with HgCl<sub>2</sub> + Vitamin E (0.5 ml/day + 200 mg/kg/day respectively)

At the termination of experiment (21<sup>st</sup> day) animals were sacrificed and the testis were quickly excised out and

<sup>1</sup>Corresponding author

fixed in Bouin's fixative. Following the routine procedure, slides containing 5  $\mu$  paraffin sections were prepared. The sections were stained with haematoxylin and eosin. Histopathological changes were noted in control, experimental and recovery groups of animals.

#### Statistical analysis

The data generated for each mouse were considered for calculation of Mean  $\pm$  SEM for different groups of mice. Comparison was made in between vehicle control group with that of the HgCl<sub>2</sub> treated group of mice and also the data generated from HgCl<sub>2</sub> + vitamins groups were compared with HgCl<sub>2</sub> treated group. Statistical evaluation of data was done following Students "t" test.

## RESULTS

### Control and Treated groups

In this period the animals were sexually immature with ripen testis. The testis remained apparently in normal developing condition in 7, 14 and 21 days of control groups (Figs. 1, 3 and 5). In 7 days treatment the testis of 28 days old mice exhibited some structural deformities. The seminiferous tubules were irregular in shape and intertubular connective tissues were discontinuous (Fig.2). In 14 days treatment the testes of 35 days old mice showed more deformation than 7 days treatment. The seminiferous tubules were slightly oblong in shape and cellular units were lost their proper arrangements in the lumen of the tubules. The necrotic changes were noted in the spermatogonia, primary and secondary spermatocytes (Fig. 4). In 21 days treated (42 days old) mice testis exhibited much more pronounced changes in their histological structure. The seminiferous tubules exhibited big vacuole in their lumen due to toxic load. In some of the tubules the epithelial lining were detached. The spermatogenic series of cells appeared to be slightly condensed, dyscohesive and detached at places. The spermatogonia were deformed and the cytoplasm became vacuolated and granular. Many spermatocytes showed pyknotic nuclei and faintly stained cytoplasm (apoptotic cells). The spermatids became hypertrophied and Sertoli cells were damaged and only deformed nuclear material were visible. Degenerative changes were also seen in the Leydig cells and connective

tissue (Fig. 6).The diameter of all cellular elements were significantly ( $P < 0.001$ ) reduced.(Tables 1, 2 and 3).

### Antioxidant supplemented groups

The toxic effects were reduced in testis of antioxidants supplemented animals. In 7 days mercury + vitamin C (MC) treated group, the seminiferous tubules were oval in shape and exhibited active developing stage with cellular units (Fig. 7), while in mercury + vitamin E (ME) administrated group showed thick tunica albuginea and many big and dividing spermatogonia inside the tubules (Fig. 8). In 14 days recovery period of MC group exhibited rounded shape seminiferous tubules and many newly formed spermatogenic cells arranged properly inside the tubules (Fig. 9). In ME group during 14 days recovery, the elongation of seminiferous tubules still persisted. Reformation of spermatogenic cells were observed in this group (Fig.10). In 21 days recovery period of MC group exhibited almost rounded shape seminiferous tubules. All stages of spermatogenesis were clearly visible and spreaded in the lumen of the tubules as were seen in the corresponding control (Fig. 11), while in ME group showed partial protection against mercury toxicity. The spermatogenic cells exhibited less recovery and did not show normal cytological structure. The Sertoli cells were not clearly seen in the section (Fig. 12). The diameter of seminiferous tubules and other spermatogenic cells were greater than mercury treated group (Tables 1, 2 and 3).

## DISCUSSION

Exposure of mice to mercuric chloride during pre pubertal period of life induced significant effects on spermatogenesis in testis of mice. Rao *et al.* (1990) reported degenerative changes in testicular tissue and accessory reproductive organs due to lead administration at the dose of 1, 2, 4, and 6 mg/kg to male rats. They revealed that inhibition of steroidogenesis and level of testosterone was decline. Similarly Chowdhury and Arora (1982) studied testicular degeneration and cellular deformation in the seminiferous tubules and Leydig cells due to administration of HgCl<sub>2</sub> (0.5 mg/kg) to rat, mice, guinea pigs and hamsters.

In the present investigation, the mercuric chloride

**SHARMA AND BHATTACHARYA: ROLE OF SOME ANTIOXIDANTS ON MERCURY CHLORIDE INDUCED SPERMATOGENESIS...**

exposed group exhibited testicular damage in 7, 14 and 21 days of duration in pre pubertal phase of mice and our observation agree with the results of Nagar and Bhattacharya (2001). They reported abnormal configuration of seminiferous tubules and deformed spermatogenic cells in the testis of mercuric chloride treated mice at the dose of 0.5 ml/day. Mercuric chloride at the dose of 0.5 mg/kg/body weight and 1 mg/kg/body weight for a period of 30 days, decreased level of testosterone, FSH, and LH in rat reported by Ramlingam et al. (2003). It appears from the present study that alternation in cholesterol and testosterone level due to the mercuric chloride intoxication which inhibits the spermatogenesis in mice.

In the present investigation, the animals were treated simultaneously with mercury and antioxidants (vitamin C and E) showed protection against mercury induced cytotoxicity alterations. The seminiferous tubules showed less shrinkage and reorganized and malformation of different spermatogenic cells were reduced. Various investigators have reported the significance of the administration of vitamin C and E in histological damage induced by various toxicants. Mishra and Acharya (2004) reported that supplementation of vitamin E and C (100 mg/kg/body weight) along with lead acetate (10

mg/kg/body weight) prevents the lead induced oxidative damage of germinal cells of male mice. Similarly Chinoy and Sharma (1998) reported amelioration of fluoride toxicity by vitamin E and D in reproductive organs of male mice. Ghosh et al. (2002) reported that vitamin C and E ameliorate oxidative stress related testicular impairment in animal tissue. The present study demonstrated that the protection seen in testes at the pre pubertal period of mice after administration of vitamin C appeared to be more effective than those observed with vitamin E.

On the basis of this study it is concluded that mercury causes severe toxic tissue damage in all segments of the testis at pre pubertal phase of life. This damage may be caused by the reactive oxygen species produced by mercury within the animals body. Antioxidant vitamins interact with mercury ions, neutralize them or bind with transition metals and prevent the ROS mediated oxidative damage in testes and protect the tissue as in the following descending order of effectiveness vitamin C > vitamin E.

**ACKNOWLEDGEMENTS**

Authors are thankful to Dr. S.C. Kothari, Professor and Head School of Studies in Zoology and Biotechnology, Vikram University, Ujjain (M.P.), for providing necessary laboratory facilities during this investigation.

**Table 1 : Diameter of different spermatogenic stages of control, treated and recovery groups of 28 days old mice**

S. No.	Parameter	Control	Treated	Recovery by Vitamin E	Recovery by Vitamin C
1	Thickness of Tunica albuginea	.450±0.001	0.385±0.009*	0.465±0.06**	0.470±0.08**
2	Seminiferous tubules	6.50±0.19	6.78±0.011 <sup>NS</sup>	6.65±0.016 <sup>NS</sup>	6.85±0.017 <sup>NS</sup>
3	Spermatogonia	0.42±0.01	0.35±0.05*	0.37±0.01 <sup>NS</sup>	0.43±0.01*
4	Primary spermatocytes	0.38±0.04	0.34±0.07 <sup>NS</sup>	0.36±0.02 <sup>NS</sup>	0.37±0.03 <sup>NS</sup>
5	Secondary spermatocytes	0.35±0.05	0.34±0.02 <sup>NS</sup>	0.36±0.01 <sup>NS</sup>	0.36±0.05 <sup>NS</sup>
6	Sertoli cells	0.38±0.02	0.32±0.01*	0.39±0.01*	0.40±0.03*
7	Interstitial cells	0.34±0.01	0.27±0.02*	0.31±0.01 <sup>NS</sup>	0.35±0.01*

All values are expressed in ±SEM

Significant level, NS = Non significant, \* = (P<0.05), \*\* = (P<0.01)

**Table 2 : Diameter of different spermatogenic stages of control, treated and recovery groups of 35 days old mice**

S. No.	Parameters	Control	Treated	Recovery by Vitamin E	Recovery by Vitamin C
1	Thickness of Tunica albuginea	0.580±0.010	0.456±0.008**	0.485±0.002 <sup>NS</sup>	0.540±0.006*
2	Seminiferous tubules	7.50±0.19	6.89±0.012**	7.10±0.012 <sup>NS</sup>	7.90±0.01*
3	Spermatogonia	0.43±0.02	0.35±0.01**	0.40±0.02*	0.42±0.03**
4	Primary spermatocytes	0.38±0.05	0.32±0.01*	0.38±0.01*	0.41±0.01**
5	Secondary spermatocytes	0.37±0.01	0.29±0.08*	0.34±0.04 <sup>NS</sup>	0.37±0.01*
6	Spermatid	0.34±0.06	0.26±0.08*	0.33±0.01*	0.34±0.07*
7	Sertoli cells	0.39±0.03	0.28±0.01**	0.35±0.01**	0.37±0.01**
8	Interstitial cells	0.36±0.04	0.26±0.01**	0.37±0.01**	0.38±0.01**

All values are expressed in ±SEM

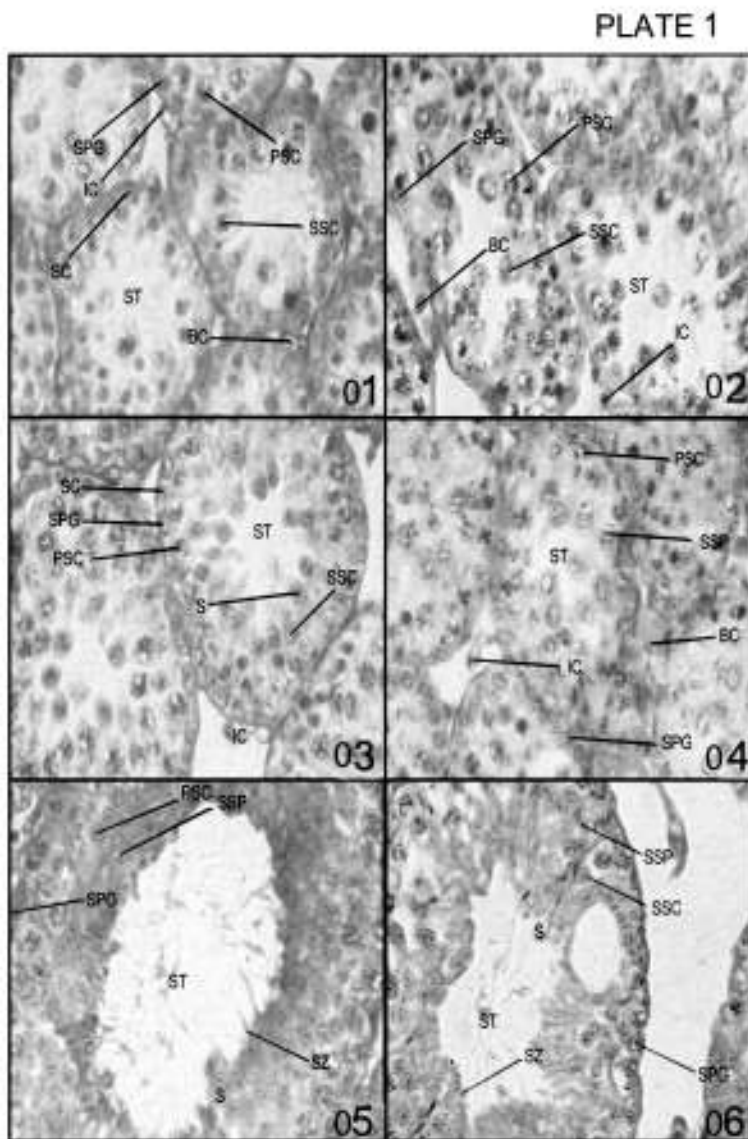
Significant level, NS = Non significant, \* = (P<0.05), \*\* = (P<0.01)

**Table 3 : Diameter of different spermatogenic stages of control, treated and recovery groups of 42 days old mice**

S. No.	Parameters	Control	Treated	Recovery by Vitamin E	Recovery by Vitamin C
1	Thickness of Tunica albuginea	0.780±0.009	0.462±0.08***	0.665±0.08***	0.785±0.09****
2	Seminiferous tubules	8.85±0.01	6.65±0.05***	7.45±0.07**	8.50±0.09****
3	Spermatogonia	0.45±0.06	0.30±0.03***	0.38±0.06**	0.43±0.08***
4	Primary spermatocytes	0.39±0.05	0.25±0.02***	0.33±0.06***	0.39±0.08***
5	Secondary spermatocytes	0.38±0.07	0.24±0.01****	0.35±0.04**	0.37±0.08***
6	Spermatids	0.35±0.08	0.24±0.04***	0.26±0.08 <sup>NS</sup>	0.32±0.09**
7	Sperm	0.34±0.01	0.23±0.02***	0.30±0.06**	0.35±0.08***
8	Sertoli cells	0.40±0.07	0.25±0.03***	0.32±0.06**	0.38±0.08***
9	Interstitial cells	0.38±0.05	0.24±0.02***	0.32±0.06*	0.37±0.07***

All values are expressed in ±SEM

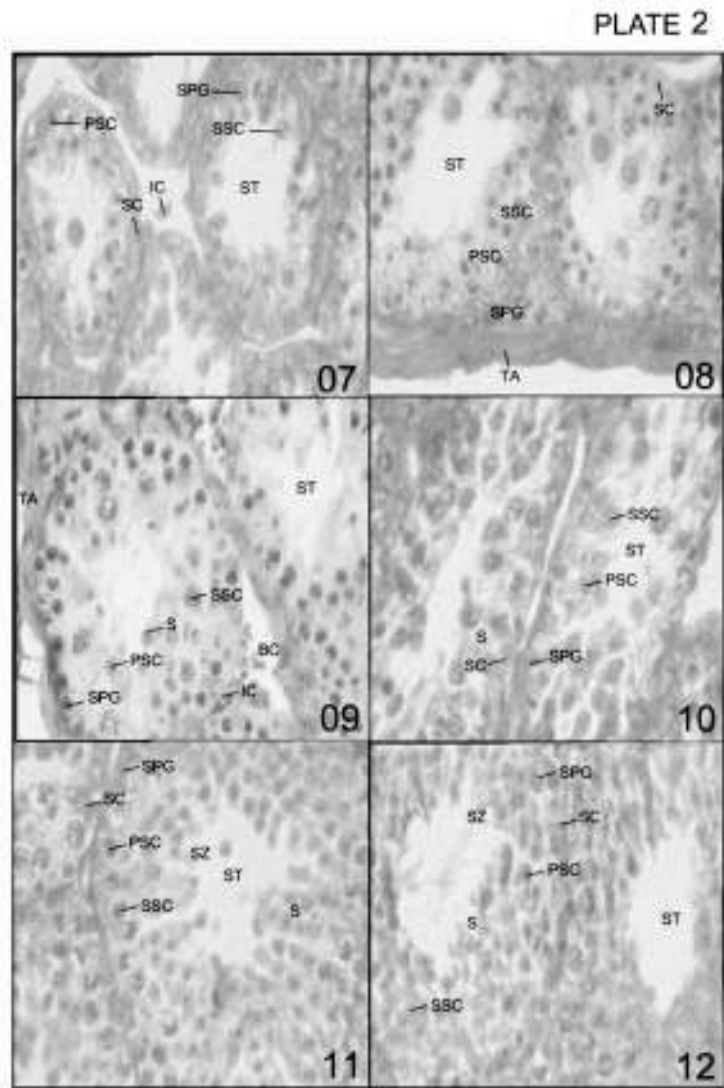
Significant level, NS = Non significant, \* = (P<0.05), \*\* = (P<0.01) \*\*\* (P<0.001)



**Fig. 1** Control group (28 days old mice testis) showing developing seminiferous tubules.  
**Fig. 2** Treated group (28 days old mice testis) Exhibiting irregular seminiferous tubules  
**Fig. 3** Control group (35 days old mice testis) showing compact appearance of seminiferous tubules with developing spermatogenic cells.  
**Fig. 4** Treated group (35 days old mice testis) showing oblong seminiferous tubules with necrotic changes in developing spermatogenic cells.  
**Fig. 5** Control group (42 days old mice testis) Exhibiting fully developed seminiferous tubules.  
**Fig. 6** Treated group (42 days old mice testis) showing damage seminiferous tubules with big vacuole inside the lumen due to toxic load of mercury.

**Abbreviations -**

**BC= Blood Cells , IC= Interstitial Cell , PSC= Primary spermatocytes  
 S=Spermatid, SC=Sertoli cell, SPG=Spermatogonia, SSC=Secondary spermatocytes  
 ST= Seminiferous tubules, SZ= Spermatozoa**



**Fig. 7** Recovery with Vit. C (28 days old mice testis) showing oval shaped seminiferous tubules with active developing stages of spermatogenic cells.

**Fig. 8** Recovery with Vit. E (28 days old mice testis) showing thick tunica albuginea and many dividing cells inside the tubules.

**Fig. 9** Recovery with Vit. C (35 days old mice testis) Exhibiting seminiferous tubules with Many newly formed spermatogenic cells.

**Fig. 10** Recovery with Vit. E (35 days old mice testis) showing elongated seminiferous tubules big and dividing spermatogenic cells.

**Fig. 11** Recovery with Vit. C (42 days old mice testis) showing compact seminiferous tubules with all stages of spermatogenesis.

**Fig. 12** Fig. 11 Recovery with Vit. E (42 days old mice testis) showing seminiferous tubules with partial recovery.

**Abbreviations -**

**BC= Blood Cells , IC= Interstitial Cell , PSC= Primary spermatocytes  
 S=Spermatid, SC=Sertoli cell, SPG=Spermatogonia, SSC=Secondary spermatocytes  
 ST= Seminiferous tubules, SZ= Spermatozoa**

## REFERENCES

- Acharya U.R., Rathore R.M. and Mishra M.; 2003. Role of vitamin C on lead acetate induced spermatogenesis in Swiss mice. *Environ. Toxicol. Pharmacol.*, **13**: 9-14.
- Banu R. and Sharma R; 2005. Protective effect of vitamins (E and C) on lead induced hepatotoxicity in male Swiss mice. *Journal of cell and Tissu Research*, **5(1)**: 293-298.
- Chowdhary A.R. and Arora V.; 1982. Toxic effects of mercury on testes in different animal species. *Ind. J. Physiol. Pharmacol.*, **26**: 246-248.
- Chinoy N.J. and Sharma A.K.; 1998. Amelioration of fluoride toxicity by vitamin E and D in reproductive function of male mice. *Fluoride*, **31**: 203-216.
- Ernst. E., Madsen M.M. and Danscher G.; 1991. Ultrastructural demonstration of mercury in Sertoli and Leydig cells of the rat following methyl mercuric chloride or mercuric chloride treatment. *Reprod. Toxicol.*, **5**: 205-209.
- Ghosh D., Das U.B. and Mishra M.; 2002. Protective role of  $\alpha$ -tocopherol succinate (provitamin E) in cyclophosphamide induce testicular gemitogenic steroidogenic disorders. *Rad. Res.*, **36**: 1199-1208.
- Keck C., Bergman M., Ernst. E., Mooler C., Klinsch S. and Nieschlag E.; 1993. Autometallographic detection of mercury in testicular tissue of an infertile man exposed to mercury vapour. *Reprod. Toxicol.*, **7**: 469-475.
- Mishra M. and Acharya U.R.; 2004. Protective action of vitamins on the spermatogenesis in lead treated Swiss mice. *J. Trace. Elements. Medicin. Bio.*, **18**: 173-178.
- Mohamed M.K., Thomas M., Burbacher T.M. and Mottet N.K. ;1987. Effects of methyl mercury on testicular functions in *Macaca fascicularis* Monkeys. *Pharmacol. Toxicol.*, **60**: 29-36.
- Nagar R.N. and Bhattacharya L.; 2001. Effect of mercuric chloride on testicular activities in mice *Muscular albinus*. *J. Environ. Biol.*, **22(1)**: 15-18.
- Patil G.R. and Rao M.V.; 1999. Role of ascorbic acid on mercuric chloride toxicity in vital organs of mice. *Indian J. Environ. Toxicol.*, **9(2)**: 53-55.
- Rao A., Choudhary A.R. and Vachharajani K.D.; 1987. Effect of mercuric chloride on hydrolytic enzymes of rat testicular tissue. *Ind. J. Exp. Biol.*, **25**: 542-547.
- Rao R.V., N.J. and Choudhary A.R.; 1990. Recovery of histological changes in reproductive organs of male rats after withdrawal of lead treatment. *Proc. Nat. Acad. Sci. India*, **60(B)**: 186-195.
- Ramlingam V., Vimaladavi V., Rajashwary S. and Suryavathi V.; 2003. Effect of mercuric chloride on circulating hormones in adult albino mice. *J. Environ. Biol.*, **24(4)**: 401-404.