

## APEXIFICATION WITH RAPID MTA PLUG TECHNIQUE

**BABITA AHLAWAT<sup>1a</sup>, ASHOK KUMAR<sup>b</sup>, NAVDHA CHAUDHARY<sup>c</sup>, VIJAYLAXMY<sup>d</sup> AND VINOD BHARDWAJ<sup>e</sup>**

<sup>a</sup>Department of Dentistry, SHKM GMC, Nalhar, Mewat, Haryana India

<sup>b</sup>Department of ENT, SHKM GMC, Nalhar, Mewat, Haryana. India

<sup>c</sup>Department of Pedodontics and Preventive Dentistry, Eklavya Dental College, Kotputli Dist. Jaipur, Rajasthan. India

<sup>d</sup>Department of Dentistry, SHKM GMC, Nalhar, Mewat, Haryana. India

<sup>e</sup>Department of Pharmacology, SHKM GMC, Nalhar, Mewat, Haryana. India

### ABSTRACT

**Immature permanent teeth create an endodontic challenge for complete asepsis and three dimensional obturation of the root canal system. Apexification forms an apical barrier or a stop against which one can place root canal filling material avoiding over extrusion. Until recently, the most widely accepted material of choice for apexification was Ca(OH)<sub>2</sub> but its many disadvantages has gradually steered clinicians toward the use of alternative material such as mineral trioxide aggregate (MTA) as an apical barrier. Presented herewith is a clinical case report wherein non-vital young permanent tooth was being managed using apexification with MTA.**

**KEYWORDS :** Apexification, MTA, Apical plug

The completion of root development and closure of the apex occurs up to 3 years after eruption of the tooth. Unfortunately traumatic injuries to these young permanent teeth are not uncommon and are said to affect 30% of children (Andreasen and Andreasen, 1994). The majority of these incidents occur before root formation is complete and may result in pulpal inflammation or necrosis. Premature loss of a functioning pulp results in a fragile tooth with a compromised crown/root ratio, thin dentin walls and a wide and often apically diverging root that presents significant endodontic challenges.

There is absence of natural apical constriction which creates an endodontic challenge for complete asepsis and three dimensional obturation of the root canal system. Therefore one of the aims of endodontic treatment is to form an apical barrier or a stop against which one can place root canal filling material avoiding over extrusion. This technique is termed as apexification. Apexification, or root end closure, is the process whereby a non-vital, immature, permanent tooth which has lost the capacity for further root development is induced to form a calcified barrier at the root terminus. This barrier forms a matrix against which root canal filling or restorative material can be compacted with length control. Thus, apexification is regarded as a treatment of last resort in immature teeth which have lost pulp vitality.

In the past, techniques for management were confined to custom fitting the filling material, paste fills and apical surgery. Although the Apexification technique with Ca(OH)<sub>2</sub> has enjoyed considerable tooth preserving success, many disadvantages of this protracted treatment have justified a search for alternatives, such as artificial barrier techniques with their potential for more rapid treatment for example Mineral trioxide aggregate (MTA).

MTA was first introduced by Torabinejad et al into the field of endodontics in 1993, developed at Loma Linda University and has gained much popularity since. MTA is a powder consisting of fine hydrophilic particles of tricalcium silicate, tricalcium oxide and silicate oxide. It has low solubility and a radiopacity that is slightly greater than that of dentin. This material has demonstrated good sealability and biocompatibility (Torabinejad et al, 1993, Torabinejad et al, 1995). MTA has a pH of 12.5 after setting which is similar to the pH of calcium hydroxide and it has been suggested that this may impart some antimicrobial properties. Apexification with MTA has several advantages including improved patient compliance, reduced cost of clinical time and the ability to securely restore the tooth at an earlier stage. The risk of tooth fracture after long term Ca(OH)<sub>2</sub> medication is also eliminated. Presented herewith is a clinical case report wherein non-vital young permanent tooth was being managed using apexification with MTA.

---

<sup>1</sup>Corresponding author

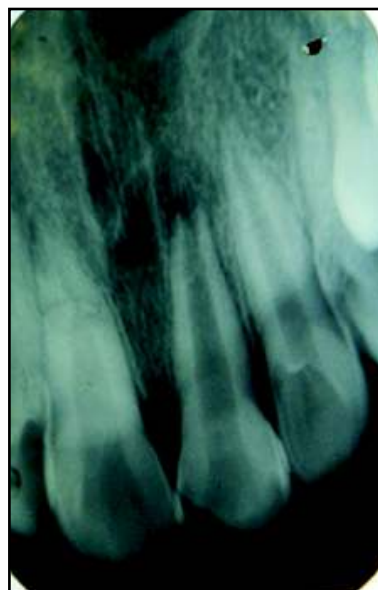
### Case Report

An 11-year old male reported to the Outpatient Department of Pediatric and Preventive Dentistry, BRS Dental College & Hospital, Panchkula (Haryana) with a chief complaint of broken upper left front tooth with a history of trauma two and a half years back. The patient started noticing that the tooth is becoming discoloured since last six months. The preoperative radiograph (Figure1) revealed an open apex with 11 & periapical radiolucency. The tooth did not respond with pulp sensitivity tests. A diagnosis of Ellis Class IV fracture with Cvek's stage 4 root development was made. Access opening was done. The working length was determined radiographically (Figure2). Cleaning and shaping was done by light hand filing as the dentinal walls were thin. Irrigation was done with 3% sodium hypochlorite & normal saline. The canal was dried using paper points followed by placement of calcium hydroxide paste as intracanal medicament for 1 week (Figure3). The access cavity was sealed with temporary cement. In the next appointment, the canal was dried using paper points after irrigation with 3% sodium hypochlorite and saline. Mineral trioxide aggregate (MTA) was mixed with distilled water to sandy consistency. The mix was placed with Amalgam carrier and increments were condensed with hand pluggers till thickness of 4 mm (Figure4). A wet cotton pellet was placed and access cavity was sealed. The following day, obturation was done and access cavity sealed with Composite (Figure5).

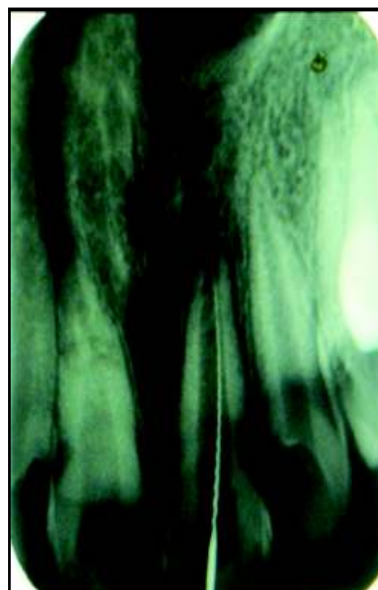### DISCUSSION

The mature permanent teeth can survive for a lifetime without the support of a vital pulp but for the immature permanent tooth, the future is less secure as the absence of natural constriction at the root canal end makes it difficult to control the filling materials. Because of the lack of an apical constriction, Apexification or root end closure has been advocated.

The use of custom fitted gutta-percha cones, but this is not advisable as the apical portion of the root is frequently wider than the coronal portion, making proper condensation of the gutta-percha impossible. Sufficient widening of the coronal segment to make its diameter greater than that of the apical portion would significantly



**Figure 1: Pre-operative Radiograph of 21 Showing Open Apex**

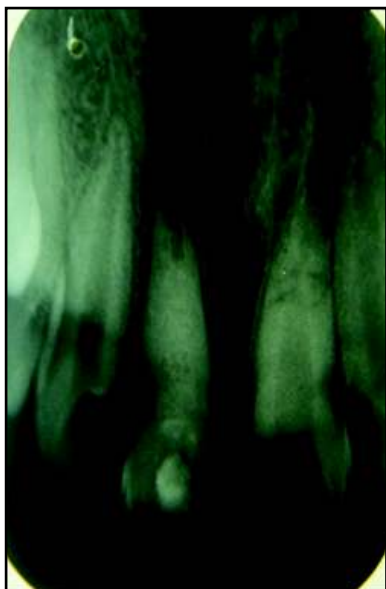


**Figure 2 : Working Length Determination**

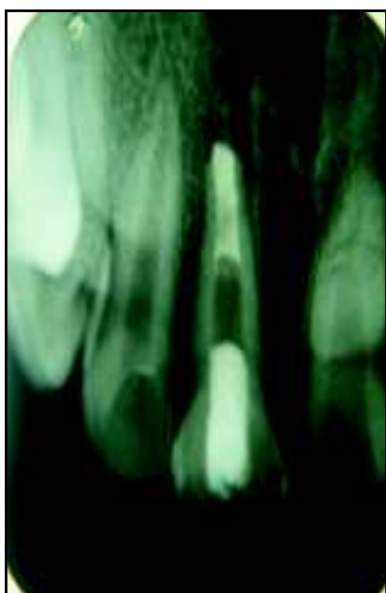
weaken the root and increase the risk of fracture.

Before the introduction of conservative apical closure techniques, the usual approach to this problem was surgical. Although this could be successful, psychological and patient management issues in patients who are usually young children offered many contraindications. A more predictable and less traumatic approach was desirable.

Until recently, the most widely accepted technique



**Figure 3 : Calcium Hydroxide Pushed As An Intra-Canal Medicament**



**Figure 4 : MTA- Apical Plug**

has involved cleaning and filling the canal with a temporary paste, most commonly  $\text{Ca(OH)}_2$ , alone or in combination with other drugs, to promote apexification. Comparable outcomes have been noted in humans and animals with tricalcium phosphate, collagen calcium phosphate, osteogenic protein-1, bone growth factors and a number of other material. Apexification using calcium hydroxide requires multiple visits and could take a year or more to

achieve a complete apical barrier that would allow root canal filling using gutta-percha and sealer. The time needed depends on stage of root development and status of periapical tissue. Although the clinical success rates for  $\text{Ca(OH)}_2$  apexification is high, complications like risk of reinfection and root fracture has gradually steered clinician toward the use of alternative material such as mineral trioxide aggregate (MTA) as an apical barrier.

MTA apical barrier technique can be introduced as an alternative to calcium hydroxide apexification. Successful outcome of MTA apexification has been reported (Holden et al, 2008). The essence of this treatment approach lies in the expedient cleaning and shaping of the root canal system, followed by replacement of an apical seal with a material that is amenable to tissue healing and regeneration (Steinig et al, 2003 and Matt et al, 2004). MTA apexification may be performed as a one- or two-visit procedure and alleviate the need for extended period of dressing with  $\text{Ca(OH)}_2$ . This technique also allows for immediate restoration and reduces the potential of catastrophic, vertical or oblique root fracture that often affects such teeth. MTA has a unique advantage because one of the problems often found in those cases is the presence of tissue fluid or exudation into the canals.

MTA as an apexification material represents a primary monoblock. Appetite like interfacial deposits form during the maturation of MTA result in filling the gap induced during material shrinkage phase and improves the frictional resistance of MTA to root canal walls. The formation of nonbonding and gap filling appetite crystals also accounts for seal of MTA. So, keeping these in view, MTA was chosen for the present case. The root canal was medicated for 1 week with  $\text{Ca(OH)}_2$  to raise the acidic pH of the inflamed periapical tissues before permanently sealing as research has suggested that tissue pH may affect the hydration reaction and final physical properties of MTA (Lee et al, 2004).

The apical plug created with MTA can be interpreted as an artificial barrier to condense the subsequent root canal filling material, in order to prevent reinfection of the canal system. Some authors have postulated that possible leakage of MTA could be influenced by the thickness of the apical plug. A recent study

reported that the orthograde use of MTA provided an adequate seal against bacterial infiltration regardless of the thickness of the apical plug (Leimburg et al, 2004). This result is in agreement with Hachmeister et al who underlined that the thickness of the apical plug may have a significant impact only on displacement resistance (Hachmeister et al, 2002).

MTA has superior biocompatibility and it is less cytotoxic due to its alkaline pH and presence of calcium and phosphate ions in its formulation results in capacity to attract blastic cells and promote favourable environment for cementum deposition. An apical plug of 4-5mm thickness is usually considered optimal (Valois and Costa, 2004).

The novel approach of Apexification using MTA lessens the patient's treatment time between first appointment and final restoration. Importance of this approach lies in thorough cleaning of root canal followed by apical seal with material that favours regeneration. In addition there is less chance of root fracture in immature teeth with thin roots because the material immediately bonds with the roots and strengthens it (Kubasad and Ghivari, 2011).

The choice of treatment regimen for teeth with open apices depends on the individual case and operator experience and familiarity with handling the various materials. Patient availability for follow-up appointments should be considered as well if multiple sessions are required (Raldi et al, 2009).

## CONCLUSION

Apexification with a novel biocompatible material like MTA is a new boon in effective management of teeth with open apex. This innovative procedure is predictable and less time consuming one.

## REFERENCES

Andreasen JO, Andreasen FM. Textbook and color atlas of traumatic injuries to the teeth, 3rd ed. Copenhagen: Munksgaard; 1994.

- de Leimburg ML, Angeretti A, Ceruti P, Lendini M, Pasqualini D, Berutti E. MTA obturation of pulpless teeth with open apices: bacterial leakage as detected by polymerase chain reaction assay. *J Endod* 2004; 30: 883-886.
- Holden DT, Schwartz SA, Kirkpatrick TC et al. Clinical outcomes of artificial root-end barriers with mineral trioxide aggregate in teeth with immature apices. *J Endod* 2008; 34 (7): 812-817.
- Hachmeister DR, Schindler G, Walker WA, Thomas DD. The sealing ability and retention characteristics of mineral trioxide aggregate in a model of apexification. *J Endod* 2002; 28: 386-390.
- Kubasad GC, Ghivari SB. Apexification with apical plug of MTA-Report of cases. *Archives of Oral Sciences & Research* 2011; 1 (2): 104-107.
- Lee YL, Lee BS, Lin FH, Yun Lin A, Lan Wh, Lin CP. Effects of physiological environments on the hydration behaviour of mineral trioxide aggregate. *Biomaterials* 2004; 25: 787.
- Matt GD, Thorpe JR, Strother JM et al. Comparative study of white and gray mineral trioxide aggregate (MTA) simulating a one- or two-step apical barrier technique. *J Endod* 2004; 30 (12): 876-879.
- Raldi DP, Mello I, Habitante SM, Lage-Marques JL, Coil J. Treatment Options for Teeth with Open Apices and Apical Periodontitis. *J Can Dent Assoc.* 2009; 75 (8): 591-596.
- Steinig T. H., Regan J. D. and Gutmann J. L., 2003. The use and predictable placement of mineral trioxide aggregate in one-visit apexification cases. *Aust Endod J.*, 29 (1): 34-42.
- Torabinejad M., Watson T. F., Pitt Ford T. R., 1993. Sealing ability of mineral trioxide aggregate when used as a root end filling material. *J Endod*, 19: 591-595.
- Torabinejad M., Hong C. U. and Lee S. J., 1995. Investigation of mineral trioxide aggregate for root end filling in dogs. *J Endod*, 21: 603-608.
- Valois C. R. and Costa E. D., 2004. Jr. Influence of the thickness of mineral trioxide aggregate on scaling ability of root end fillings in vitro. *Oral Surg Oral Med Oral Pathol Oral Radiol Endod*, 97: 108.