

OPACIFIED FOLDABLE INTRAOCULAR LENS AFTER CATARACT SURGERY MANAGED WITH INTRAOCULAR LENS EXCHANGE

PRAJAKTA MODAK¹

Sankara Eye Hospital, Bangalore, India

ABSTRACT

A patient presented to us with diminution of vision 2 years after cataract surgery with IOL (intraocular lens) implantation in the right eye. On examination, visual acuity was counting fingers close to face. Slit lamp examination revealed an opacified intraocular lens. IOL exchange was planned with standby anterior vitrectomy and iris claw lens in view of possibility of capsular fibrosis and risk of with-the-bag removal of IOL. IOL exchange was successfully done without damaging the posterior capsule and rigid IOL was placed in the bag. Postoperatively, best corrected visual acuity was 6/9; and the patient was satisfied with the surgical outcome. Opacification of foldable IOL may often be misdiagnosed as posterior capsular opacification. Though rare, IOL opacification has to be considered after careful clinical examination as a cause of poor visual acuity post cataract surgery. It may occur due to calcified deposits on the IOL. Definitive management in the form of IOL exchange can result in good postoperative outcome.

KEYWORDS: Opacified IOL, IOL Exchange

Silicone, hydrogel, and acrylic (hydrophilic and hydrophobic) are the principal materials used for manufacturing IOLs that can be folded to be inserted into the eye through a small self-sealing incision. Dystrophic calcification of IOLs is a rare phenomenon following cataract surgery. Many case reports have been described about such occurrences in literature. (Goodall and Ghosh, 2004). This calcification is seen on anterior surface, posterior surface as well as within the IOL optic. IOL opacification can occur at various periods of time following cataract surgery. Late opacification of foldable IOL may be associated with capsular fibrosis and IOL may have to be removed with the bag. We present a rare case of opacified foldable IOL presenting 3 years after the cataract surgery, for which IOL exchange was successfully done without removal of the bag and rigid IOL was implanted in the bag.

CASE REPORT

A 60 years old female patient presented to us with the complaints of diminution of vision of the right eye since 1 year. She had a history of cataract surgery with intraocular lens implantation in both eyes 3 years ago. The pre-, post-, and intra-operative period was uneventful. The surgeries had good visual outcome. The patient did not undergo any other ocular surgical procedure. The patient was asymptomatic for 2 years postoperatively when she started to notice glare in her vision in the right eye, which gradually progressed to diminished vision in the right eye.

There was no history of any systemic comorbidities. Records of previous cataract surgery were not available.

On examination, best corrected visual acuity of the right eye was counting fingers close to face. Slit lamp examination revealed a clear cornea, quiet anterior chamber with pseudophakia and opacification at the pupillary area which was provisionally diagnosed as posterior capsular opacification. However, careful slit lamp examination after pupillary dilation revealed that the entire IOL itself was opacified. (Figure 1) Fundus could not be seen due to the opacified IOL. Best corrected visual acuity of the left eye was 6/9, slit lamp examination showed a quiet anterior chamber with pseudophakia, fundus examination was within normal limits with a cup disc ratio of 0.4: 1 and a normal foveal reflex.

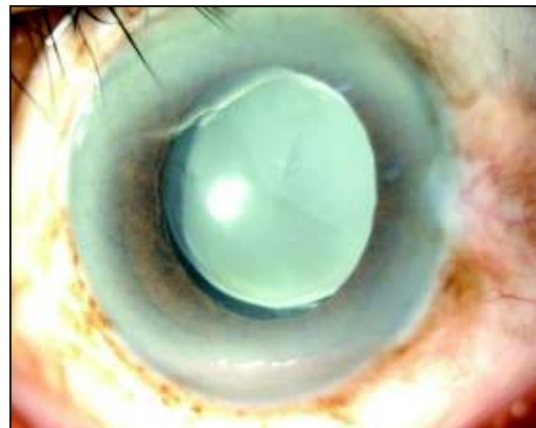


Figure 1: Opacified IOL

¹Corresponding author

IOL exchange was planned for the right eye. Accurate IOL power calculation was done in pseudophakic mode. Since the IOL was implanted 3 years ago, we anticipated difficulty in separating the IOL from the capsular margin. Since there was a possibility of capsular fibrosis precluding the IOL removal, with-the bag IOL removal was considered; anterior vitrectomy and iris claw lens were kept standby.

SURGICAL PROCEDURE

Peribulbar anesthesia was given. A temporal sclerocorneal tunnel was made. Rhexis margin was separated from IOL using iris reposer and ocular viscoelastic. The haptics of the IOL were carefully untucked and brought into the anterior chamber, taking care not to damage the posterior capsule. The opacified foldable IOL was explanted through the scleral tunnel (Figure 2) and rigid IOL was implanted in the bag. (Figure 3) Postoperatively, topical antibiotic and steroid eyedrops (ofloxacin + dexamethasone) were prescribed in tapering dose.

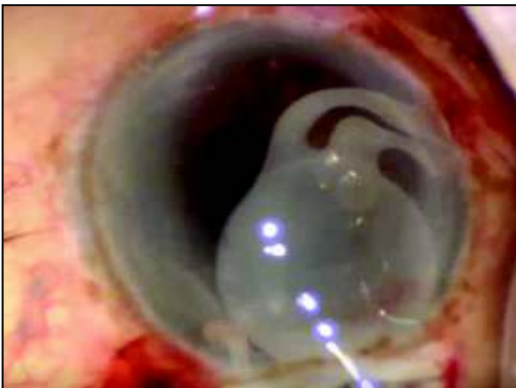


Figure 2: IOL Explantation

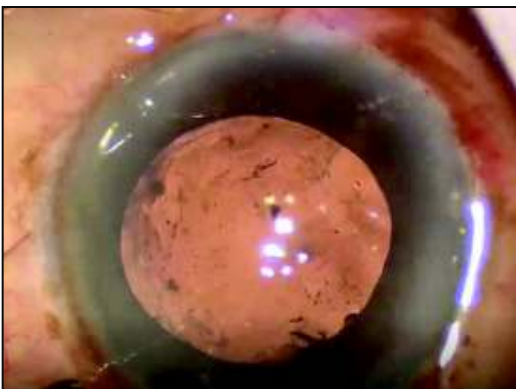


Figure 3: PCIOL in bag

RESULTS

At 2 weeks followup, BCVA was 6/9 and fundus examination revealed an epiretinal membrane. The patient was satisfied with the postoperative outcome.

DISCUSSION

The advent of phacoemulsification and the increasing use of foldable IOLs have given rise to new complications including late opacification of intraocular lenses. This opacification results from calcium phosphate deposits on the surfaces or the internal substance of the lens. Majority of these case reports were seen to occur in patients with asteroid hyalosis and hydrophilic acrylic lenses (Foot *et al.*, 2004). These cases are often misdiagnosed as posterior capsular opacification; with an unsuccessful attempt at YAG capsulotomy. Surgical explantation of IOLs is required in cases of vision threatening opacification. The operative procedure is challenging due to the tight adherence of the IOL to the capsular bag. Complications include zonular dehiscence, rupture of the posterior capsule and corneal decompensation. (Al-Bdour and Dahabreh, 2008) As per our knowledge, this is the first case report in which a 3 year old opacified IOL has been explanted without posterior capsular complications.

Though rare, IOL opacification should be considered as a cause of poor visual acuity post cataract surgery. Careful clinical examination on slit lamp is of paramount importance. Definitive management in the form of IOL exchange has good postoperative visual outcome.

REFERENCES

- Al-Bdour M.D. and Dahabreh L.S., 2008. Late opacification of a hydrophilic acrylic intraocular lens. Middle East Afr. J. Ophthalmol., **15**(1):37–38. doi:10.4103/0974-9233.53374.
- Foot L., Werner L., Gills J.P., Shoemaker D.W., Phillips P.S. and Mamalis N., 2004. Surface calcification of silicone plate intraocular lenses in patients with asteroid hyalosis. Am. J. Ophthalmol, **137**:979-87.
- Goodall K.L. and Ghosh Y.K., 2004. Total Opacification of Intraocular Lens Implant After Uncomplicated Cataract Surgery: A Case Series. Arch. Ophthalmol., **122**(5): 782–784. doi:10.1001/archoph.122.5.782.