

## SURGICAL MANAGEMENT OF A COMPLEX ODONTOMA - A CASE REPORT

NAVDHA CHAUDHARY<sup>a</sup>, BABITA AHLAWAT<sup>1b</sup>, ASHOK KUMAR<sup>c</sup>, VIJAYLAXMY<sup>d</sup> AND VINOD BHARDWAJ<sup>e</sup>

<sup>a</sup>Department of Pedodontics and Preventive Dentistry, Eklavya Dental College, Kotputli, Jaipur, Rajasthan, India

<sup>bc</sup>Department of Dentistry, SHKM GMC, Nalhar, Mewat, Haryana, India

<sup>c</sup>Department of ENT, SHKM GMC, Nalhar, Mewat, Haryana, India

<sup>d</sup>Department of Pharmacology, SHKM GMC, Nalhar, Mewat, Haryana, India

### ABSTRACT

**Odontomas, the hamartomatous lesions, occur somewhat more frequently in maxilla than in mandible. Compound type more often seen in anterior maxilla and complex odontoma occur more often in the molar region of either jaw. They are generally discovered on routine radiographic examination. This case report represents surgical removal of a complex odontoma of anterior maxilla which is a rare occurrence.**

**KEYWORDS :** Complex odontoma, Compound odontoma, Hamartomatous Lesions, Odontoma

Odontomas are mixed odontogenic tumors in which both the epithelial and mesenchymal components undergo functional differentiation and form enamel and dentin (Regezi et al, 2003). They are hamartomatous lesions rather than true neoplasms. (Neville et al, 2002 and Sharma et al, 2010 and Shafer et al, 2009 and Iwamoto et al, 1999)

According to WHO classification (1992), two types of odontomas have been acknowledged:

- Compound odontomas malformations with representation of all dental tissues and exhibiting an orderly distribution in which numerous tooth-like structures known as denticles are found.
- Complex odontomas malformations in which all dental tissues are likewise represented, but showing a disorganized distribution.

Compound odontoma is approximately twice as common as complex odontoma.

This lesion is composed of more than one type of tissue, and for this reason, has been called a composite odontoma

Accordingly we have,

- Complex composite odontoma
- Compound composite odontoma

Although odontomas are generally asymptomatic but there are certain clinical indicators which include:

- Retention of deciduous teeth
- Noneruption of permanent teeth
- Expansion of cortical bone
- Tooth displacement.

Other symptoms include paresthesia in lower lip and swelling in the affected area.

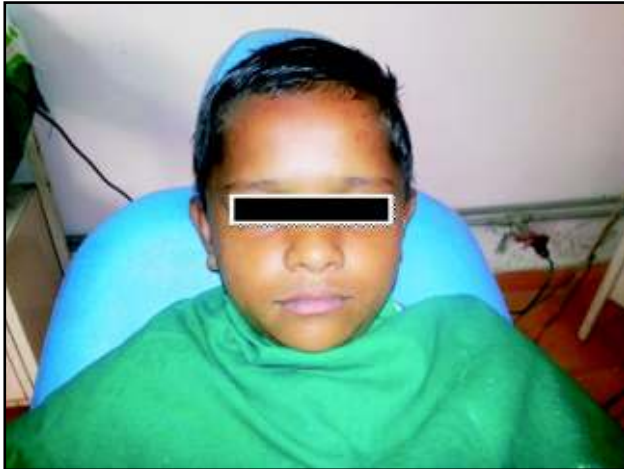Odontomas occur somewhat more frequently in the maxilla than in the mandible. Compound type more often seen in the anterior maxilla and complex odontomas occur more often in the molar region of either jaw. They are generally discovered on routine radiographic examination or when films are taken to determine the reason for failure of a tooth to erupt.

### Case Report

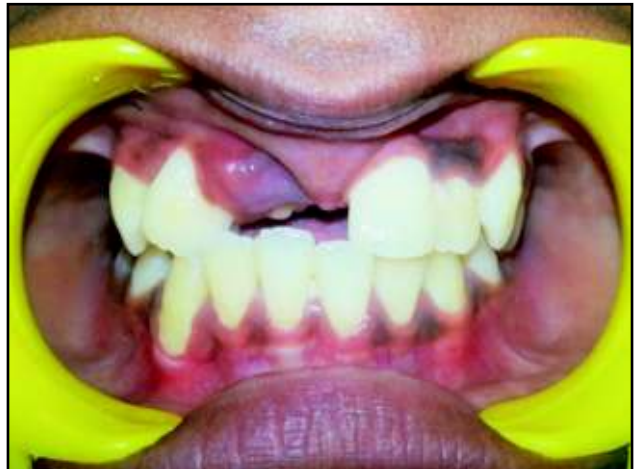A 12 year old boy reported to the Department of Paedodontics and Preventive Dentistry, B.R.S Dental College, Panchkula, with a chief complaint of irregularly placed and widely spaced upper front teeth [Figure 1]. Clinical examination revealed distal displacement of right maxillary central incisor and right maxillary lateral incisor was placed palatal to it. A tooth like mass was appreciated erupting palatally in the region of right maxillary central incisor [Figure 2,3]. There was no complaint of any pain or swelling in the affected region.

An orthopantomograph and an occlusal radiograph revealed the presence of fused globular masses of tooth like radiopacity in the anterior maxillary region, which resulted in wide distal displacement and crowding of right maxillary incisors [Figure 4,5]. A provisional diagnosis of odontoma was made and surgical excision was planned for the same. A mucoperiosteal flap was raised extending from labial aspect of central incisor on left side to the distal of right canine (Figure 6). Surgical approach was performed

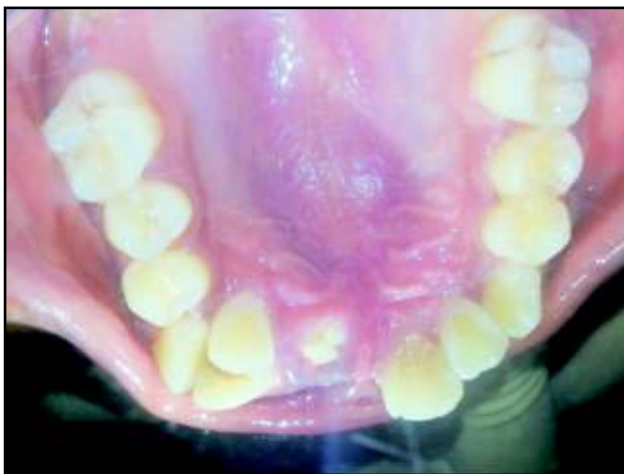<sup>1</sup>Corresponding author



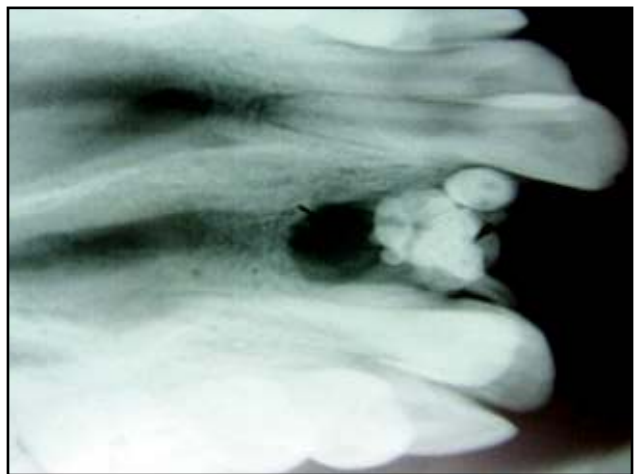**Figure 1 : Front view Photograph of the Patient**



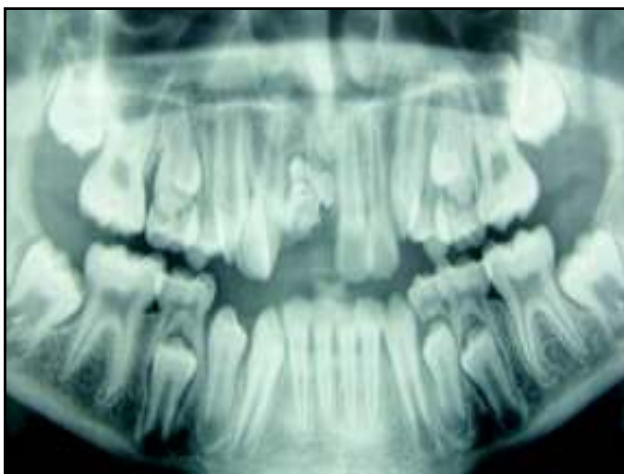**Figure 2 : Pre-Operative Photograph Front View**



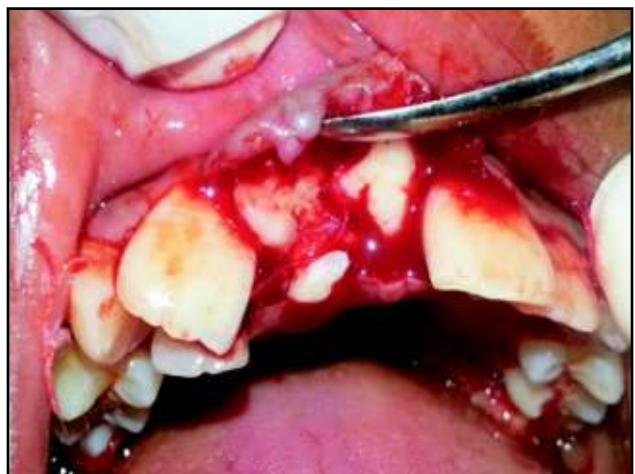**Figure 3 : Pre-Operative Photograph Intraoral View**



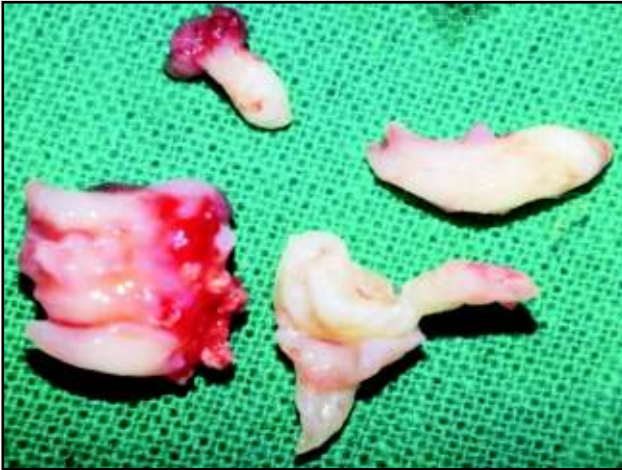**Figure 4 : Occlusal Radiograph**



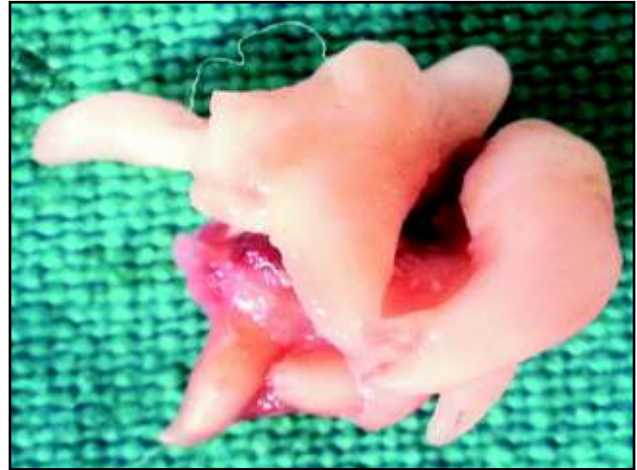**Figure 5 : Orthopantomographic View**



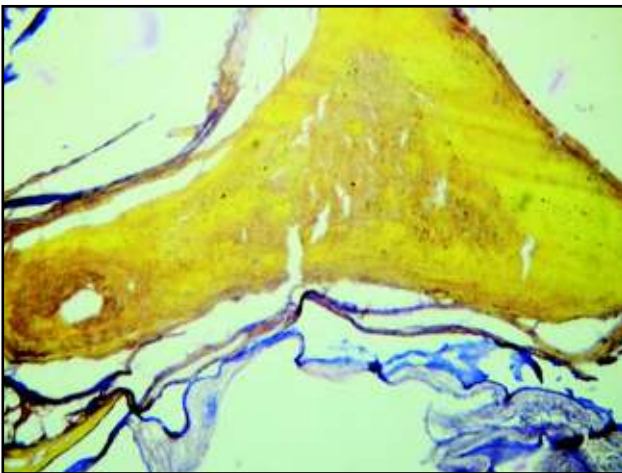
**Figure 6 : A Mucoperiosteal Flap Was Raised Extending From Labial Aspect of Central Incisor on Left Side to the Distal of Right Canine.**



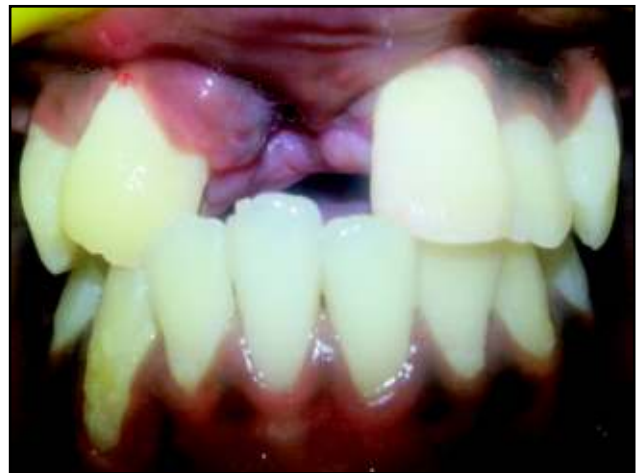**Figure 7 : Several Blocks of Odontoma Removed.**



**Figure 8 : The Excised Bony Masses Measuring Around 2.0x 1.5 X 1.0 Cm Sent For Histopathological Evaluation**



**Figure 9 : Histologic View**



**Figure 10 : Post-operative View After 1 Week**

using a #6 spherical drill and a #704 tapered stem, and several blocks of odontoma were removed[Figure 7]. The surgical cavity was totally smoothed and no complementary treatment was found necessary. Mucoperiosteal flap was closed with interrupted sutures. Postoperative medication consisted of antibiotics and analgesics for 7 days.

The excised bony masses measured around 2.0X 1.5 X 1.0 cm and were sent for histopathological evaluation[Figure 8].

Histopathological report showed an irregular arrangement of dental tissues such as enamel, dentin and cementum, together with odontoblastic cells in pulp tissue,

which confirmed the diagnosis of complex odontoma. The underlying tissue was unremarkable with no evidence of inflammation or atypia and thus ruled out presence of any cystic lining[Figure 9].

The sutures were removed after 1 week and patient had no pain or any signs of intraoral swelling or inflammation[Figure 10].After a follow up period of one month, a laser frenectomy followed by a fixed orthodontic treatment was planned for the alignment of maxillary anterior teeth.

## DISCUSSION

The complex odontoma occurs predominantly in the molar region of the mandible and less often in the anterior maxilla. They are often associated with the crowns of unerupted teeth and occasionally may take the place of a tooth or displace the associated erupted tooth. For these reasons they may be discovered, when small, as incidental findings when investigating a patient with a tooth missing from the dental arch. As the lesion enlarges it usually presents as a painless, slow-growing expansion of the jaw, but may become infected and present with pain, particularly if it communicates with the mouth. Multiple odontomas are rare.

Radiographically, a fully formed complex odontoma appears as a radiopaque lesion, sometimes with a radiating structure, but in the developing stages it shows as a well-defined radiolucent lesion in which there is progressive deposition of radiopaque material as calcification of the dental tissues proceeds. The mature lesion is surrounded by a narrow radiolucent zone analogous to the pericoronal space around unerupted teeth.

Histologically, a fully developed complex odontoma consists of a mass of irregularly arranged, but well-formed enamel, dentin, and cementum. Dentin forms the bulk of the lesion and, on surfaces not covered by enamel or cementum, is in contact with tissue resembling the normal pulp. In decalcified sections, the areas occupied by enamel appear as empty spaces except where enamel maturation is incomplete when the spaces contain remnants of enamel matrix with a fibrillar appearance. The developing complex odontoma will contain varying amounts of soft tissue which include odontogenic epithelium and mesenchyme, and structures resembling enamel organs. Developing lesions show histological features of all stages in odontogenesis and may be difficult to differentiate from ameloblastic fibroma and ameloblastic fibro-odontoma.

In general, because of the small dimension of the lesions and its uneventful biological behavior, a conservative surgical enucleation is recommended, and no cases of recurrence have been reported so far (Mortellaro et al, 2008 and Ozeç, 2007). However, enucleation of large

odontomas may affect adjacent bone and teeth (Biocic et al, 2010). In the present case, the lesion was totally and carefully removed and no damage to the adjacent developing teeth or the thinned basal cortical bone was produced.

As a result of the odontogenic nature, including epithelial and mesenchymal tissue, odontomas can develop cystic transformation into dentigerous cyst. This cyst results from the cystic degeneration of enamel organ after partial or total development of the crown, cystic transformation of the follicle associated with the unerupted tooth may also occur when its eruption is impeded by the odontoma (Shah et al, 2010). The odontomas are well encapsulated and recurrence is usually not observed if the lining epithelium is removed intact. Large complex odontomas should be cut into segments for removal, in order to conserve normal bone and to prevent jaw fracture that can result if excessive elevative force is applied in areas of the lesion that lack encapsulation and may be fused to surrounding bone (Fonseca, 2000); a technique which was used in our case also. If portions of the lesion are left unexcised, such residual odontomas remain unchanged throughout the years in studies (Marx, 2003).

## REFERENCES

- Biocic J., Macan D., Brajdic D., Manojlovic S., Butorac-Rakvin L., Hat J., and 2010. Large erupting complex odontoma in a dentigerous cyst removed by a piecemeal resection. *Pediatr Dent.*, 32:255-259.
- Fonseca R. J., 2000. Odontogenic Tumors Surgical pathology and Management. In Williams TP, Stewart JC (eds), *Oral and Maxillofacial Surgery*. Philadelphia, Saunders, :379-81.
- Iwamoto O., Harada H., Kusukawa J., Kameyama T., 1999. Multiple Odontomas of the Mandible - A Case Report. *J Oral Maxillofac Surg.*, 57:338-41.
- Mortellaro C., Berrone M., Turatti G., Rimondini L., DelPrever A. B., Canavese F., et al., 2008. Odontogenic tumors in childhood: a retrospective study of 86 treated cases. Importance of a correct histopathologic diagnosis. *J Craniofac Surg.*, 19:1173-1178.

- Marx R. E., Stern D., 2003. Odontogenic Tumors Hamartomas and Neoplasms. In Bywaters L (ed). Oral and Maxillofacial Pathology. Hong Kong, Quintessence Publishing Co, Inc., 1:637-8.
- Neville B. W., Damm D. D., Allen C., Bouquot J. E., 2002. Odontogenic Tumors. In Ellen Forest (ed), Oral and Maxillofacial Pathology, 2nd Ed. Philadelphia, Saunders, : 631-2.
- Ozeç I., Kiliç E., Yeler H., Goze F. and Yeler D., 2007. Large complex odontoma associated with a primary tooth. Quintessence Int., **38**:521-524.
- Regezi J. A., Sciubba J. J. and Jordan R. C., 2003. Odontogenic Tumors. In Penny Rudolf (ed), Oral Pathology 4th Ed. Missouri, Saunders, : 286-8.
- Shah A., Singh M. and Chowdhury S., 2010. Complex Odontoma associated with dentigerous cyst. Int J Clin Dent Sci., **1**:89-92.
- Sharma U., Sharma R., Gulati A., Yadav R. and Gauba K., 2010. Compound composite odontoma with unusual number of denticles A rare entity. Saudi Dent J., **22**:145-9.
- Shafer W. G., Hine M. K. and Levy B. M., 2009. A Textbook of Oral Pathology, 6th Ed. Noida: Elsevier, Odontogenic tumors.
- Shah U., Sharma R., Gulati A., Yadav R. and Gauba K., 2010. Compound composite odontoma with unusual number of denticles A rare entity. Saudi Dent J., **22**:145-9.